

Peripapillary Intrachoroidal Cavitation, A Rare Finding in Myopic Eye: A Case Report

Saeed Karimi¹, Mohsen Zare^{1,*}, Omid Emadi¹, Shima Azizi¹

1. Department of Ophthalmology, Torfeh Medical Center, Shahid Beheshti University of Medical Sciences, Tehran, Iran

* **Corresponding author:** Mohsen Zare, MD. Torfeh Hospital, Mustafa Khomeini Street, in front of the Islamic Organization, Email: mohsenzare95@gmail.com

Received 2025 January 26; Accepted 2025 May 11.

Abstract

Background: To describe peripapillary intrathyroidal cavitation in a patient with pathologic myopia and to summarize the literature on its pathophysiology, clinical manifestations, and diagnostic imaging using optical coherence tomography.

Case Presentation: We present an asymptomatic 65-year-old man with high myopia who was referred to our clinic with a suspected peripapillary choroidal tumor in the left eye. A comprehensive ophthalmologic examination was conducted. Anterior segment exam showed bilateral moderate crystalline lens opacity. A Fundus exam showed classic myopic fundus changes, including a tilted optic disc, posterior staphyloma, chorioretinal atrophy in both eyes, and a peripapillary yellow lesion raising suspicion for choroidal cavitation in the left eye. The diagnosis was confirmed with swept-source optical coherence tomography by demonstrating an intrachoroidal hyporeflective area beneath healthy RPE and scleral posterior bowing, compatible with choroidal cavitation.

Conclusion: Peripapillary intrachoroidal cavitation should be considered a differential diagnosis of congenital disc malformations, peripapillary choroidal neovascularization, and choroidal tumors in myopic eyes.

Keywords: Peripapillary Intrachoroidal Cavitation, Pathological Myopia, Optical Coherence Tomography.

1. Background

Peripapillary intrachoroidal cavitation (PICC) was first noticed by Freund et al. via optical coherence tomography (OCT) in 20 high myopic eyes. He described it as a yellow-orange protrusion of the retina and retinal pigment epithelium (RPE) at the lower border of the myopic conus and called it peripapillary detachment in pathologic myopia (1). Toranzo et al. described it as a lesion inside the choroid where the RPE and retina above it are normal (2).

The prevalence of PICC has been reported to be 2.2% in myopic eyes and

22% in high myopic eyes (3). There are also reports of non-peripapillary and peripapillary intrachoroidal cavitation in hyperopic or emmetropic eyes (4-6).

Its risk factors and pathogenesis are unknown, but posterior sclera bowing under PICC without deformation in the retina or RPE seems to play a role in its occurrence (7).

PICC is usually asymptomatic. It appears as a yellow-orange lesion, usually on the inferior border of the optic nerve head (2). OCT shows an intrachoroidal hyporeflective area below the sclera's normal RPE and posterior bowing (6). Differential diagnoses are optic pit, optic disc drusen, disc coloboma, dysplastic disc, CNV, and choroidal tumors.

Published data on PICC complications is limited. Associated macular detachment (8), macular hole (9), or retinoschisis (6) have been reported. The prognosis usually depends on the myopia complication itself. Without further complications, PICC needs no therapeutic intervention, and clinical significance mainly focuses on its differentials.

Here, we represent a 65 male with PICC, initially suspected of a peripapillary choroidal tumor. The diagnosis was confirmed using swept-source optical coherence tomography (SS-OCT).

2. Case report

In June 2024, a 65-year-old asymptomatic man was referred to Torfeh Hospital Retina Clinic with suspected peripapillary choroidal

malignancy in his left eye. His visual acuity with a correction of -4.50 diopters was at the level of counting fingers at 1.5 meters in the right eye and 6/10 in the left eye with the same correction.

Anterior segment examination was normal with bilateral moderate crystalline lens opacity. Intraocular pressure (IOP) was 13 mmHg in both eyes, measured using a Goldmann tonometer. Posterior segment examination showed bilateral myopic changes, including tilted optic discs and bilateral posterior staphyloma. He had a 0.6 cup-to-disc ratio with healthy rims on the right and 0.8 with inferior rim loss and adjacent disc hemorrhage in the left eye. Additionally, a round-to-oval lesion in the peripapillary region was noted in the left eye, while no such lesion was observed in the right eye ([Figure 1](#)).

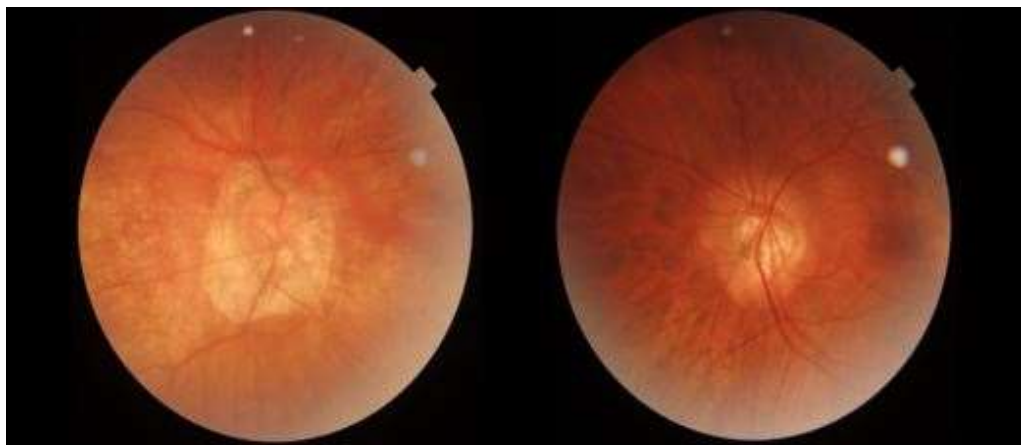


Figure 1. Fundus photograph of the right (A) and the left eye (B). A. Shows tilted disc, posterior staphyloma, tessellation and chorioretinal atrophy in macular area. B. Shows tilted disc and fundus tessellation and a peripapillary yellow-orange patch. There is also small splinter hemorrhage in inferior quadrant of optic nerve head.

Suspecting PICC, fundus photography, and SS-OCT were ordered. Choroidal hyporeflective area and scleral posterior bowing under normal RPE were noticed without subretinal fluid ([Figure 2](#)). The patient was also referred to the glaucoma clinic for further evaluation. Unfortunately, he did not return for further investigations, including a visual field examination.

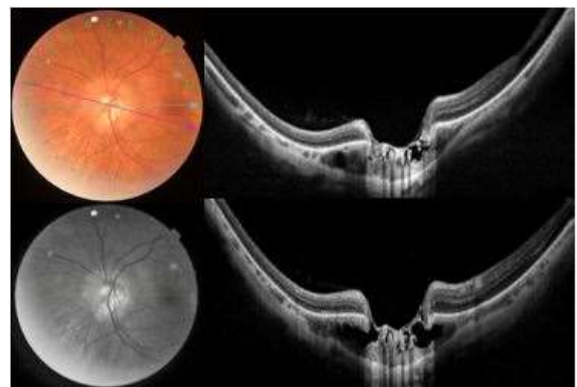


Figure 2. A. Fundus Photo. B. Red free image C (blue arrow), D (purple arrow). SS-OCT of the left eye shows intrachoroidal cavitation and scleral posterior bowing beneath a normal RPE and retina.

3. Discussion

PICC is a distinct yellow-orange lesion found at the outer border of the myopic conus. Despite being considered benign, PICC can present visual field defects similar to those seen in glaucoma, contributing to diagnostic challenges. Misdiagnosis as a choroidal amelanotic tumor can result in unnecessary interventions (10). Additionally, PICC can lead to macular detachment and retinoschisis.

The introduction of OCT has significantly improved the visualization of ocular structures, providing a better understanding of PICC (11). Recent suggestions point to high optic nerve sheath traction forces during eye movements in highly myopic eyes as potential promoters of PICC (12). The author previously suggested that an optic disc pit can play a role in PICC formation via a connection between vitreous and choroidal cavities (13). In eyes with pathologic myopia, progressive scleral thinning in the peripapillary area leads to choroidal disintegration. Possible connections between choroid and vitreous through optic nerve head defects can cause cavitation in the choroid. It has also been suggested that a weaker structure in the peripapillary area of myopic eyes can facilitate the absorption of vitreous with aging (2). Toranzo et al. hypothesized that progressive peripapillary staphyloma suggests structural defects in collagenous layers between the choroid and the optic nerve. Cell adhesion molecules such as cadherin and adherin may also play a role. (14) It has been proposed that PICC and choroidal schisis represent different stages of the same pathologic spectrum. The preferential localization in the inferior peripapillary region may suggest a possible role of gravitational forces.

In our case, PICC was misdiagnosed as a choroidal tumor. SS-OCT showed characteristic findings. The patient also had a large cup-to-disc ratio, inferior rim loss, and disc hemorrhage despite normal IOPs, suggesting normal-tension glaucoma, which he refused to

perform further investigations. Given the nature of normal-tension glaucoma and its potential to cause deep central and paracentral scotomas, the absence of prompt clinical assessment may result in late noticed visual function decline (15).

4. Conclusion

Peripapillary intrachoroidal cavitation should be considered a differential diagnosis of congenital disc malformations, peripapillary choroidal neovascularization, and choroidal tumors in myopic eyes. "SS-OCT is useful in differentiating PICC in myopic eyes from more critical conditions such as CNV or choroidal malignancies that require therapeutic intervention."

Acknowledgements: not applicable.

Availability of data and materials: Not applicable (already published related data in the text).

Conflicts of interests: The authors declare they have no competing interests.

Consent for publication: Not Applicable

Ethics approval and consent to participate: Written informed consent was obtained from the patient to publish this case report and accompanying images. A copy of the written consent is available for review.

Financial disclosure: Not applicable (There is no funding).

Author contributions: S. K. made the diagnosis, supervised, and confirmed the draft. M.Z., O. E, Sh. A. gathered the data and drafted the manuscript.

Transparency statement: The corresponding author (Reza Asadi) affirms that this manuscript is an honest, accurate, and transparent account of the study being reported; that no important aspects of the study have been omitted; and that any

discrepancies from the study as planned (and if relevant, registered) have been explained. All authors have read and approved the final version of the manuscript. The corresponding author also had full access to all of the data in this study and takes complete responsibility for the integrity of the data and the accuracy of the data analysis.

References

- Freund KB, Ciardella AP, Yannuzzi LA, Pece A, Goldbaum M, Kokame GT, et al. Peripapillary detachment in pathologic myopia. *Archives of Ophthalmology*. 2003;121(2):197-204. <https://doi.org/10.1001/archophth.121.2.197> PMID:12583785
- Toranzo J, Cohen SY, Erginay A, Gaudric A. Peripapillary intrachoroidal cavitation in myopia. *American journal of ophthalmology*. 2005;140(4):731-2. <https://doi.org/10.1016/j.ajo.2005.03.063> PMID:16226529
- Choudhury F, Meuer SM, Klein R, Wang D, Torres M, Jiang X, et al. Prevalence and characteristics of myopic degeneration in an adult Chinese American population: the Chinese American eye study. *American journal of ophthalmology*. 2018;187:34-42. <https://doi.org/10.1016/j.ajo.2017.12.010> PMID:29288031 PMCID:PMC5837945
- Pichi F, Sarraf D. OPTICALLY EMPTY CHOROIDAL SPACES IN HIGH HYPEROPIA. *Retinal Cases and Brief Reports*. 2021;15(2):145-8. <https://doi.org/10.1097/ICB.0000000000000799> PMID:30045155
- Yeh S-I, Chang W-C, Wu C-H, Lan Y-W, Hsieh J-W, Tsai S, et al. Characteristics of peripapillary choroidal cavitation detected by optical coherence tomography. *Ophthalmology*. 2013;120(3):544-52. <https://doi.org/10.1016/j.optha.2012.08.028> PMID:23207174
- Akimoto M, Akagi T, Okazaki K, Chihara E. Recurrent macular detachment and retinoschisis associated with intrachoroidal cavitation in a normal eye. *Case reports in ophthalmology*. 2012;3(2):169-74. <https://doi.org/10.1159/000339292> PMID:22679435 PMCID:PMC3369248
- Spaide RF, Akiba M, Ohno-Matsui K. Evaluation of peripapillary intrachoroidal cavitation with swept source and enhanced depth imaging optical coherence tomography. *Retina*. 2012;32(6):1037-44. <https://doi.org/10.1097/IAE.0b013e318242b9c0> PMID:22466483
- Ando Y, Inoue M, Ohno-Matsui K, Kusumi Y, Iida T, Hirakata A. Macular detachment associated with intrachoroidal cavitation in nonpathological myopic eyes. *Retina*. 2015;35(10):1943-50. <https://doi.org/10.1097/IAE.0000000000000575> PMID:26035397
- Örnek N, Örnek K. Full-thickness macular hole with macular intrachoroidal cavitation in a patient with pathologic myopia. *Retinal Cases and Brief Reports*. 2020;14(4):328-30. <https://doi.org/10.1097/ICB.0000000000000720> PMID:29443802
- Azar G, Leze R, Affortit-Demoge A, Faure C. Peripapillary Intrachoroidal Cavitation in Myopia Evaluated with Multimodal Imaging Comprising "En-Face" Technique. *Case reports in ophthalmological medicine*. 2015;2015:890876. <https://doi.org/10.1155/2015/890876> PMID:26543655 PMCID:PMC4620261
- Zeppieri M, Marsili S, Enaholo ES, Shuaibu AO, Uwagboe N, Salati C, et al. Optical Coherence Tomography (OCT): A Brief Look at the Uses and Technological Evolution of Ophthalmology. *Medicina (Kaunas)*. 2023;59(12). <https://doi.org/10.3390/medicina59122114> PMID:38138217 PMCID:PMC10744394
- He W, Wei L, Liu S, Huang Z, Qi J, Zhang K, et al. Role of Optic Nerve Head Characteristics in Predicting Intraocular Pressure Spikes after Cataract Surgery in Highly Myopic Eyes. *Ophthalmol Ther*. 2023;12(4):2023-33. <https://doi.org/10.1007/s40123-023-00714-z> PMID:37178442 PMCID:PMC10287873
- Karimi S. Peripapillary Intrachoroidal Cavitation and Optic Pit in a Case of High Myopia and Glaucoma. *Journal of Ophthalmology Bina*. 2019;24(3):189 to 94
- Freund KB, Mukkamala SK, Cooney MJ. Peripapillary choroidal thickening and cavitation. *Arch Ophthalmol*. 2011;129(8):1096-7. <https://doi.org/10.1001/archophthalmol.2011.208> PMID:21825199
- Mallick J, Devi L, Malik PK, Mallick J. Update on Normal Tension Glaucoma. *J Ophthalmic Vis Res*. 2016;11(2):204-8 <https://doi.org/10.4103/2008322X.183914> PMID:27413503 PMCID:PMC4926570