

The Biometric Approach as a Novel Modified Two-Patch Technique for Complete Atrioventricular Septal Defect Repair

Mahmood Hosseinzadeh Maleki¹, Afsaneh Mohammadi², Saeed Askarzadeh³, Ahmad Safari Soltanabad⁴, Samane Daneshmand⁵, Farhad Samadie⁴, Mohsen Yaghubi^{5*}

1. Department of Cardiac Surgery, Imam Reza Hospital, Mashhad University of Medical Sciences, Mashhad, Iran

2. Department of Cardiology, Razavi Hospital, Imam Reza International University, Mashhad, Iran

3. Department of Cardiology, Imam Reza Hospital, Mashhad University of Medical Sciences, Mashhad, Iran

4. Department of Extra-Corporeal Circulation (ECC), Imam Reza Hospital, Mashhad University of Medical Sciences, Mashhad, Iran

5. Department of Extra-Corporeal Circulation (ECC), Razavi Hospital, Imam Reza International University, Mashhad, Iran

* **Corresponding author:** Mohsen Yaghubi, Department of Extra-Corporeal Circulation (ECC), Razavi Hospital, Imam Reza International University, Mashhad, Iran. Email: n.m.yaghubi@gmail.com

Received 2024 April 13; Accepted 2025 February 04.

Abstract

Background: Pediatrics with atrioventricular septal defects (AVSDs), especially the complete AVSD, have significant morbidity and mortality due to dangerous postoperative complications.

Objectives: We introduce a novel modified technique for complete atrioventricular septal defect repair with two years of follow-up.

Methods: After the cardiopulmonary bypass was established, we first measured the ventricular septal defect's width and the chordae tendineae length that are adjunct to the anterior leaflet of the mitral valve to the interventricular septum. The ventricular septal defect was then repaired in two separate stages with the biologic pattern of mitral and tricuspid valves, with the Bovine patch.

Results: Echocardiographic findings immediately after surgery and two years of follow-up revealed good left ventricular function, besides no residual atrial septal or ventricular septal defect. Also, the findings showed no evidence of mitral regurgitation and LVOT obstruction.

Conclusion: The novel technique in patients with complete atrioventricular septal defect repair accompanied by more minor postoperative short-term and long-term complications.

Keywords: Complete atrioventricular septal defect, Left ventricular outflow obstruction, Ventricular septal defect, Cardiopulmonary Bypass.

1. Background

Concurrent with increasing life expectancy due to improvements in the diagnosis and treatment of cardiovascular disease, congenital heart defect repair remains challenging, increasing morbidity and mortality (1-3). Repairing the atrioventricular septal defect (AVSD) remains the most challenging issue in this field (4).

However, advances in surgical techniques besides special critical care have significantly improved survival after AVSD repair (5). Despite the enhancement of survival, most of the problems after surgery, such as reoperation due to the mitral valve regurgitation rate, range from 6.0 to 15.5%, affected the morbidity (6).

In this novel modified surgical procedure, we introduced a new surgical approach to

complete AVSD without complications in three cases after two years of follow-up with a successful outcome.

2. Objectives

We introduce a novel modified technique for complete atrioventricular septal defect repair with two years of follow-up.

3. Methods

The operation is started through a median sternotomy, elegant dissection of the pericardium and peripheral tissues, using conventional cardiopulmonary bypass (CPB) via standard aortic and bicaval cannulation moderate systemic hypothermia. Before cannulation, heparin was prescribed, and cardiopulmonary bypass (CPB) was not initiated until active coagulation time (ACT) was over 480 seconds. The aorta is cross-

clamped, and antegrade Custodiol® cardioplegia (40 ml/Kg body weight) is delivered. The vent of the left ventricle was done through the right upper superior pulmonary vein. A right atriotomy starts from the right atrial appendage to just above the inferior vena cava.

In the novel repair setting, we first measured the width of the ventricular septal defect (VSD). Also, the length of the chordae tendineae that adjunct to the anterior leaflet of the mitral valve to the interventricular septum was measured.

As a routine technique, the cleft zone created by the opposition of superior and inferior bridging leaflets is repaired with an interrupted 7/0 prolene suture. The first saline test was done to determine the kissing point of the anterior mitral leaflet cleft (Figure 1).

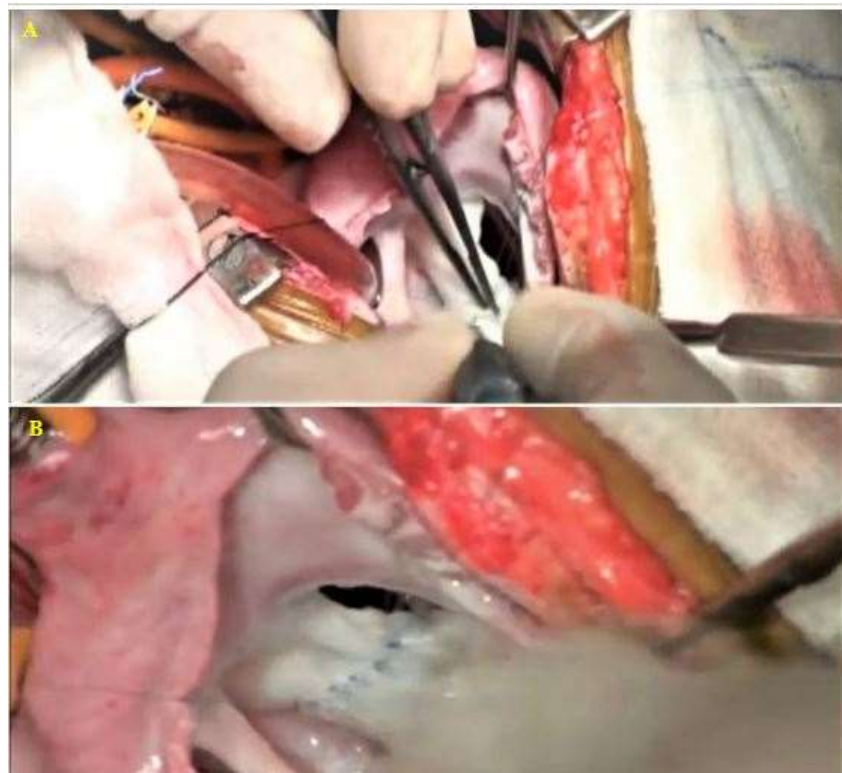


Figure 1: The cleft in the mitral valve created by the opposition of superior and inferior bridging leaflets (A). The repair of the cleft zone with an interrupted 7/0 prolene suture as a routine technique was done (B).

A Bovine patch (Edwards Lifesciences Corp, USA) was then selected with the dimension

of the width of the VSD and two-fold of the length of the anterior leaflet of the mitral

valve to the interventricular septum. After that, the patch was folded in mid-line along with the interventricular septum, and the 6/0 Prolene (Prolene, Ethicon Inc.Somerville, NJ, USA) was anastomosed to the right ventricular septum as a continuous suture.

The Bovine patch's inferior layer was anastomosed to the anterior leaflet of the annular site's mitral valve. The Bovine

patch's anterior layer was then adjusted, considering the tendinae chordae's length and anastomosed to the septal leaflet's annular site of the tricuspid valve. The saline test was performed by filling the left ventricle to evaluate the mitral valve coaptation. Then, commissural annuloplasty is performed to improve valve competence, if necessary. At this time, the VSD and mitral valve were repaired. (Figure 2).

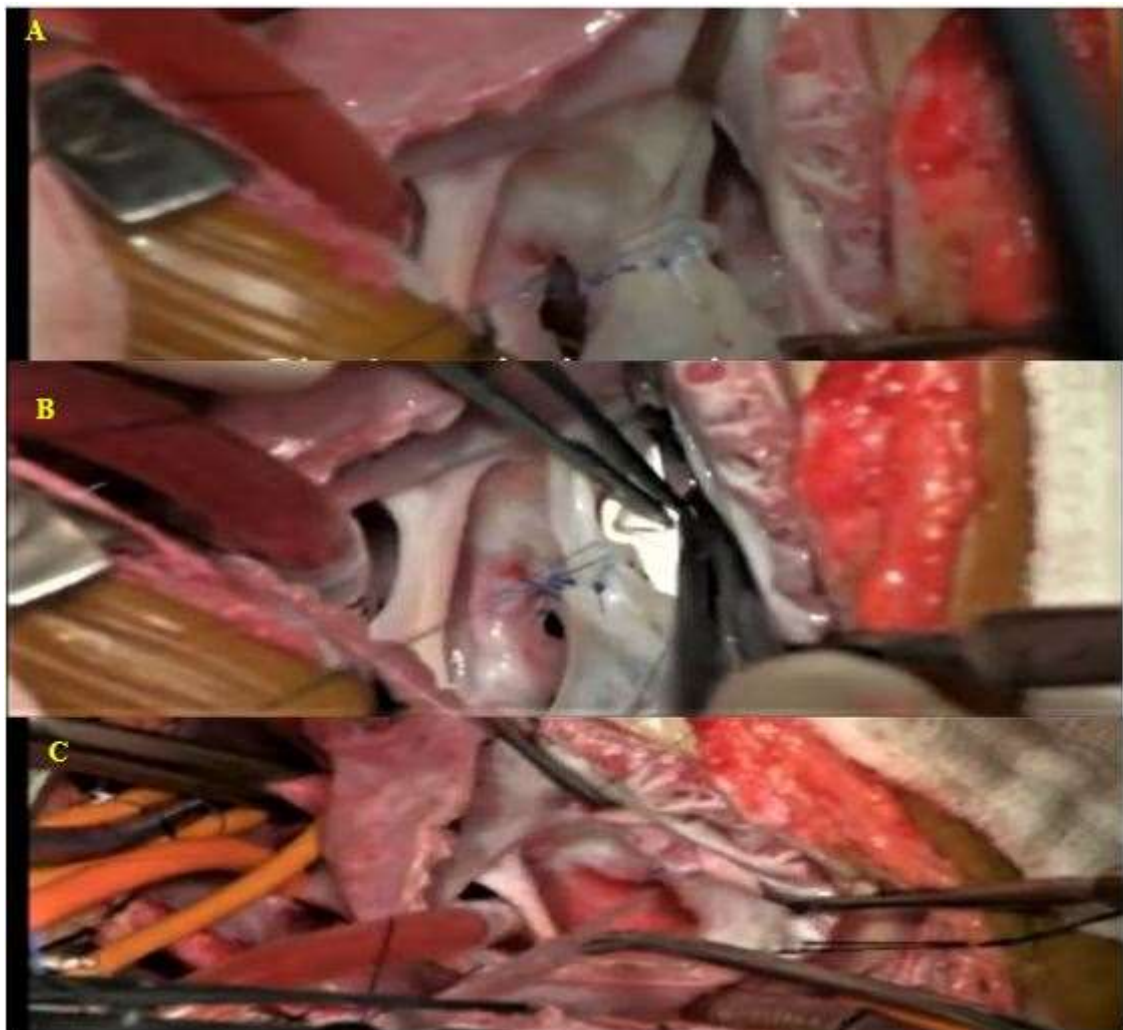


Figure 2: The Bovine patch's inferior layer was anastomosed to the anterior leaflet of the annular site's mitral valve (A). The Bovine patch's anterior layer was then adjusted and anastomosed to the septal leaflet's annular site of the tricuspid valve (B). In the final step, the saline test was done to evaluate the Mitral valve coaptation (C).

Then, we examined the posterior and anterior mitral leaflets and checked with appropriate hegar (Figure 3).

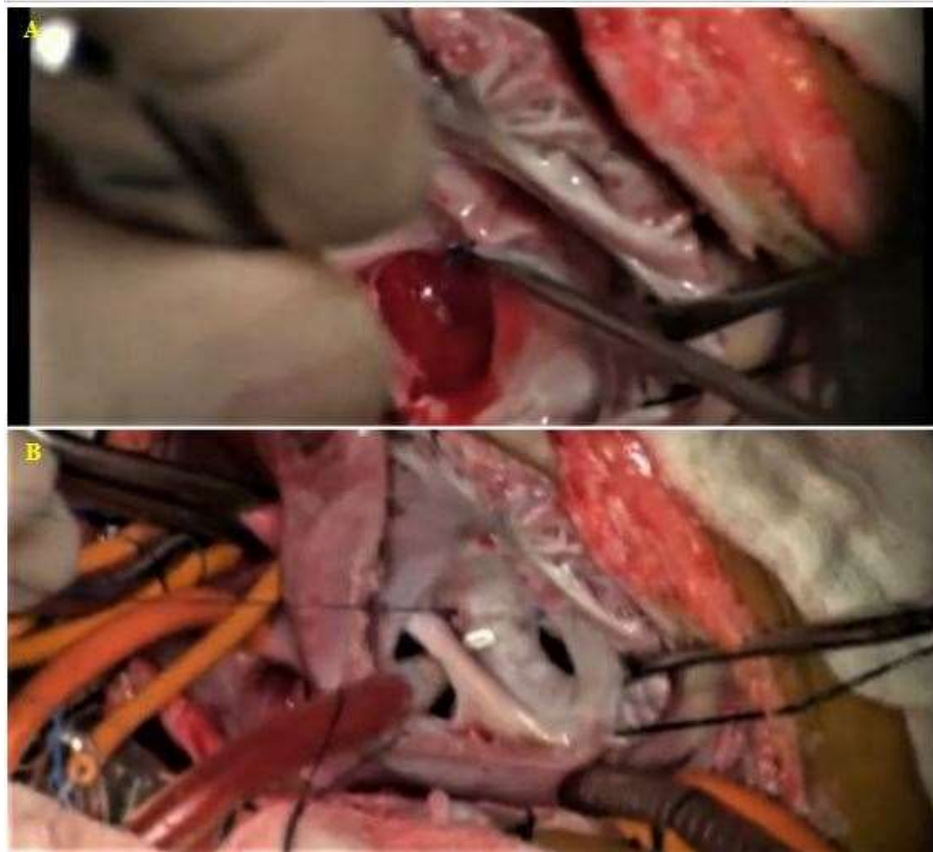


Figure 3: The examination of the PML (A) and AML (B) and checked with appropriate hegar.

Finally, the premium atrial septal defect (ASD) was closed with the autologous pericardial patch using a continuous 7/0 prolene suture starting from the annulus of the inferior bridging leaflet. The suture line is located around the atrioventricular node. Then, it goes straight onto the atrial wall and towards the coronary sinus's anterior lip to ensure drainage into the right atrium. The area around the premium ASD inferior rim was continuously sutured. Then, to close the superior rim of the premium ASD, the second 7/0 Prolene suture is started from the superior bridging leaflet annulus. The atrium is closed using the standard route with running polypropylene sutures in two layers.

The final saline test was performed to evaluate the tricuspid valve coaptation. Tricuspid valve repair was done if necessary.

The cross-clamp was removed after the patients were placed in a normothermic state and the heart was de-aired. Then, the patients were subsequently weaned off CPB. The aortic cross-clamp and CPB times were below 60 and 80 minutes in all patients, respectively.

4. Results

Early postoperative Follow-up findings:

The patients, after surgery, were transferred to pediatric cardiac surgery ICU and closely monitored. They underwent mechanical ventilation by pressured controlled synchronized intermittent mandatory ventilation (PC-SIMV). Their medication at the ICU entrance was epinephrine (0.01-0.05 mcg/kg/min) and milrinone (0.3-0.7 mcg/kg/min).

Echocardiographic findings immediately after surgery revealed good left ventricular

ejection (LVEF), no residual atrial septal defect (ASD), and ventricular septal defect (VSD). Also, the findings showed no evidence of mitral regurgitation and LVOT obstruction. Nevertheless, there was a mildly dilated right and left atrium. The results showed moderate pulmonary hypertension at this time in all patients.

Electrocardiography revealed normal sinus rhythm, narrow complex, and any conduction abnormality after the ICU entrance.

The weaning process started on the second day after ICU entrance, and the patients were weaned and then extubated on the same day. On day three, after ICU entrance, They were transferred to the post-pediatric cardiac surgery ICU. Bedside chest sonography was done and showed no evidence of pleural effusion in the right or left sides. So, the thoracic drains were removed.

Echocardiographic findings matched the results on the first day after ICU entrance. Albeit moderate pulmonary hypertension changed to a mild form. The electrocardiographic study also showed findings similar to day one after surgery, with normal sinus rhythm and no electrical disturbances.

On day seven, after ICU entrance, they were discharged in good condition without any evidence of surgical or non-surgical complications.

After discharge, their parents advised that the patients' situation should be followed by referring them to the heart clinic every four weeks until six months. In this period, they underwent close echocardiographic and electrocardiographic studies.

Two years' follow-up findings:

After the patients' discharge, their follow-up was continued for twenty-four months. The serial echocardiographic study showed the same parameters without

significant differences with the primary echocardiographic findings during this period. The serial electrocardiographic also revealed any disturbances in the electrical pathways or life-threatening or even benign dysrhythmias after discharge.

5. Discussion

Early repair of complete atrioventricular septal defects (CAVSD) in the infancy era carried more significant morbidity and mortality than repair performed later in life. Pediatrics with AVSDs, especially the complete AVSD, have dramatic morbidity and mortality resulting from postoperative mitral valve regurgitation, residual intracardiac shunts, postoperative pulmonary hypertension, and various life-threatening cardiac arrhythmias (5, 7).

Nevertheless, improved surgical techniques, effective myocardial protection strategies, and professional postoperative care have significantly reduced operative mortality (8-9). Many surgeons routinely used the "classic single patch" technique. However, this procedure leads to postoperative complications that may cause patients to reoperate or carry out persistent complications (10-11).

Since 1999, many surgeons reported that using the "Nunn modified single patch technique" showed better outcomes with lower rate complications such as no heart block, no significant residual VSDs, and no left ventricular outflow tract (LVOT) obstruction (12). However, mitral valve regurgitation remains the main complication of high morbidity (13-14).

Some studies have also stated that any mitral valve deformity, LVOT obstruction, or residual VSD would deteriorate further after the modified single-patch technique was repaired (15).

On the other hand, Surgical re-intervention for the development of left ventricular outflow tract obstruction left atrioventricular valve dysfunction, or residual septal defects after the

initial repair of the complete atrioventricular septal defect were not significantly different between cohorts in almost all studies (16-18). Based on the available evidence, the modified single-patch repair of the complete atrioventricular septal defect is similar to the double-patch repair regarding postoperative outcomes (19).

Thus, this procedure should be revised to decrease complications after surgery and modification of prior methods. The main superiorities of our technique over others (modified single patch, double patch, and central patch techniques) are the following:

The Bovine patch's length in our technique was the same as chordae tendineae attached to the mitral ring to the interventricular septum. So, the probability of incidence of left ventricular outflow tract obstruction is less than that of other procedures.

After the repair, the mitral valve was located in a more suitable position than the interventricular septum in our technique. Therefore, the repair of this valve was more effective than other procedures. Also, the chance of LVOT obstruction was significantly lower than that of other techniques.

Finally, the tricuspid and repaired mitral valves were located in an accurate anatomical site. With this method, this valve established better coaptation between the septal leaflet with anterior and posterior leaflets.

While the surface of the mitral and tricuspid valves was not located in normal anatomical sites using the classic single patch, Nunn modified the single patch, two patch, and even central patch techniques.

6. Conclusion

It seems to use the novel technique in patients with complete atrioventricular septal defect repair accompanied by more minor postoperative short-term and long-term complications that may affect morbidity and survival. However, in the absence of long-term follow-up of the patient's outcome with this procedure, we

would advise caution in considering this repair technique and abolish other surgical methods for repairing CAVSD.

Acknowledgements: We thank the pediatric cardiac surgery staff of Razavi Hospital, Mashhad, Iran.

Availability of data and materials: The dataset presented in the study is available on request from the corresponding author during submission or after its publication.

Conflicts of interests: The authors have no conflict of interest.

Consent for publication: Not applicable

Ethics approval and consent to participate: The Mashhad University of Medical Sciences ethics committee approved the study protocol with the number of IR.MUMS.REC.1399.082, which complies with the declaration of Helsinki.

Financial disclosure: None.

Author contributions: M. H. M, and A. M: Contributed to the conception of the work, revising the draft, approving the final version of the manuscript, and agreeing on all aspects of the work; S. A, contributed to the critical revision, and approval of the final version of the manuscript; A. S. S, and F. S, Contributed to the conception and design of the study, critical revision, and approval of the manuscript's final version; M.Y., Contributed to the conception and design of the study, drafting of the manuscript and critical revision, and approval of final version.

References

1. Maleki MH, Mousavi M, Kazemi T, Azdaki N, Sharifabad AR, Hoshyar R. Comparison of atherogenic index and lipid profiles in candidates for coronary artery bypass graft surgery versus normal people. *Pak J Pharm Sci.* 2018;31(5):1899-1902.

2. Amouzesi A, Amouzesi Z, Abbasi Teshnizi M, Moeinipour AA, Hosseinzadeh Maleki M. Off-Pump Versus On-Pump Coronary Artery Bypass Graft Surgery Outcomes During 6 Years: A Prospective Cohort Study. *Acta Med Iran*. 2017;55(9):578-584.
3. Ghanei Motlagh F, Ghasemi R, Nazari S, Yaghubi M. Successful pregnancy outcome in a 31 years old woman with uncorrected Tetralogy of Fallot; A case report. *JNKUMS*. 2017;8(3): 541-547. <https://doi.org/10.18869/acadpub.jnkums.8.3.541>
4. Schleiger A, Miera O, Peters B, Schmitt KRL, Kramer P, Buracionok J, et al. Long-term results after surgical repair of atrioventricular septal defect. *Interact CardioVasc Thorac Surg*. 2019; 28:789-96. <https://doi.org/10.1093/icvts/ivy334> PMID:30590597
5. Ginde S, Lam J, Hill GD, Cohen S, Woods RK, Mitchell ME. Long-term outcomes after surgical repair of complete atrioventricular septal defect. *J Thorac Cardiovasc Surg*. 2015; 150:369-74. <https://doi.org/10.1016/j.jtcvs.2015.05.011> PMID:26048271
6. Bakhtiary F, Takacs J, Cho MY, Razek V, Da'hner I, Doenst T et al. Longterm results after repair of complete atrioventricular septal defect with two-patch technique. *Ann Thorac Surg*. 2010; 89:1239-43. <https://doi.org/10.1016/j.athoracsur.2009.11.017> PMID:20338343
7. Stephens EH, Ibrahimiyeh AN, Yerebakan H, Yilmaz B, Chelliah A, Levasseur S, et al. Early Complete Atrioventricular Canal Repair Yields Outcomes Equivalent to Late Repair. *Ann Thorac Surg*. 2015;99(6):2109-15; discussion 2115-6. <https://doi.org/10.1016/j.athoracsur.2015.01.063> PMID:25886812
8. Chauhan S. Atrioventricular septal defects. *Ann Card Anaesth*. 2018; 21:1-3. https://doi.org/10.4103/aca.ACA_219_17 PMID:29336382 PMCID:PMC5791475
9. Fathi M, Valaei M, Ghanbari A, Ghasemi R, Yaghubi M. Comparison of Patient's Kidney Function Based on Kidney Disease Improving Global Outcomes (KDIGO) Criteria and Clinical Parameters in Isolated Coronary Artery Bypass Graft (CABG) Surgery in On-Pump and Off-pump Methods in Patients with Low Cardiac Output Syndrome (LCOS) After Surgery. *Anesth Pain Med*. 2020;10(2): e100517. <https://doi.org/10.5812/aapm.100517> PMID:32754433 PMCID:PMC7352649
10. Geoffrion TR, Singappuli K, Murala JSK. A review of the Nunn modified single patch technique for atrioventricular septal defect repair. *Transl Pediatr*. 2018;7(2):91-103.. <https://doi.org/10.21037/tp.2018.02.05> PMID:29770291 PMCID:PMC5938247
11. Mavroudis C. Atrioventricular Septal Defects (Atrioventricular Canal). In: Mavroudis C, Backer C. editors. *Atlas of Pediatric Cardiac Surgery*. London: Springer, 2015:117-29. https://doi.org/10.1007/978-1-4471-5319-1_9
12. Nicholson IA, Nunn GR, Sholler GF, Hawker RE, Cooper SG, Lau KC, et al. Simplified single patch technique for the repair of atrioventricular septal defect. *J Thorac Cardiovasc Surg*. 1999; 118:642-6. [https://doi.org/10.1016/S0022-5223\(99\)70009-7](https://doi.org/10.1016/S0022-5223(99)70009-7) PMID:10504628
13. Pan G, Song L, Zhou X, Zhao J. Complete Atrioventricular Septal Defect: Comparison of Modified Single-Patch Technique with Two-Patch Technique in Infants. *J Card Surg*. 2014; 29:251-5. <https://doi.org/10.1111/jocs.12295> PMID:24495040
14. Backer CL, Eltayeb O, Mongé MC, Costello JM. No Ventricular Septal Defect Patch Atrioventricular Septal Defect Repair. *Oper Tech Thorac Cardiovasc Surg*. 2015; 20:279-92. <https://doi.org/10.1053/j.optechstcvs.2016.02.006>
15. Salah T. Outcome of Australian Technique in Repair of Complete AV Canal Septal Defects. *J Egypt Card Thorac Surg*. 2014; 22:89-96.
16. Li D, Fan Q, Iwase T, Hirata Y, An Q. Modified Single-Patch Technique Versus Two-Patch Technique for the Repair of Complete Atrioventricular Septal Defect: A Meta-Analysis. *Pediatr Cardiol*. 2017;38(7):1456-1464. <https://doi.org/10.1007/s00246-017-1684-8> PMID:28711966
17. Yildirim O, Avsar M, Ozyuksel A, Akdemir M, Zeybek C, Demiroglu S, et al. Modified single versus double-patch technique for the repair of complete atrioventricular septal defect. *J Card Surg*. 2015;30: 595-600. <https://doi.org/10.1111/jocs.12557> PMID:25940208
18. Pan G, Song L, Zhou X, Zhao J. Complete atrioventricular septal defect: comparison of modified single-patch technique with two-patch technique in infants. *J Card Surg*. 2014; 29:251-5. <https://doi.org/10.1111/jocs.12295> PMID:24495040
19. Fong LS, Winlaw DS, Orr Y. Is the modified single-patch repair superior to the double-patch repair of complete atrioventricular septal defects?. *Interact CardioVasc Thorac Surg*. 2019;28(3):427-431 <https://doi.org/10.1093/icvts/ivy261> PMID:30239715