

Surgical Treatment of Partial Agenesis of the Left Pericardium

Tiago Cesar Mierzwa^{1,*}, Rodrigo Otavio Gama Franca², Rui Manuel Sequeira Almeida³

¹Assis Gurgacz Faculty, Parana, Brazil

²Ultrasonography Department, Cardiologist Medianeira Polyclinic Hospital, Parana, Brazil

³Assis Gurgacz Medical School, Parana, Brazil

*Corresponding author: Tiago Cesar Mierzwa, Assis Gurgacz Faculty, Avenue Towers, # 500, Cascavel, Parana, Brazil. Tel: 055-4599365400; Fax: 055-4533060220, E-mail: tti601@hotmail.com.

Received: September 4, 2013; Accepted: October 2, 2013

Introduction: The pericardial agenesis is a rare congenital anomaly. Classified as partial or total being asymptomatic in most cases, but some patients are at risk for serious complications and death, and these have indication for surgical treatment.

Case Presentation: This paper describes the case of a 21 year old patient, with atypical precordial pain, diagnosed with agenesis of the left pericardium confirmed by cardiac magnetic resonance imaging (MRI), in which a surgical correction was performed, by means of a neopericardium with bovine pericardial patch.

Discussion: Follow-up in immediate post-operative period showed that the patient had no complications and clinical improvement, and after 15 months, a new MRI showed a normal cardiac image.

Keywords: Pericardium; Surgery

1. Introduction

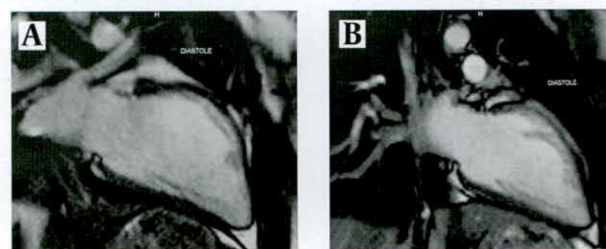
Congenital absence of the pericardium is a rare anomaly, with about 400 reported cases, in the literature (1). Most cases are asymptomatic and detected at random. With the evolution of imaging, the incidence tends to increase, due to the greater improvement of these methods in confirming the diagnosis. Magnetic resonance imaging (MRI) is the imaging method with improved accuracy, confirming the diagnosis in most cases (2). This anomaly is three times more prevalent in men, being agenesis of the left pericardium the most common presentation. The treatment of this entity is based on the risk of complications, can be clinical or surgical (1, 3). This paper reports the case of a patient aged 21 years who had a diagnosis of agenesis of the left pericardium performed by echocardiography and confirmed by MRI, surgical treatment and its short and medium term follow-up.

2. Case Presentation

A male patient, 21 years old, caucasian, previously healthy, presented with complaints of atypical chest pain, dyspnea, asthenia and dizziness, caused by physical exertion of medium intensity. Physical examination showed no particular changes and there were no previous complaints. Blood exams were normal. The chest radiograph presented a normal cardiac silhouette and mediastinal structures. The electrocardiogram showed

sinus bradycardia and diffuse changes in ventricular repolarization. Echocardiography suggested absence of the pericardium. Given these results a cardiac MRI was performed, that evidenced a left ventricular volumes slightly increased, normal systolic function and the cardiac major axis deviated to the left, herniation of the lung parenchyma, between the aorta and pulmonary trunk associated with a significant deviation from the heart to the left and posterior deviation of the aortic arch, confirming the hypothesis of agenesis of the pericardium (Figure 1A).

Figure 1. MRI Preoperative and Post-Operative



A) Preoperative MRI showing absence of left pericardium. B) MRI postoperative pericardial showing the presence or absence of left constrictions.

After this result and due to clinic precordial pain, the patient was referred for cardiac surgery. On admission there were no abnormal blood exams. The approach was performed through a median sternotomy with the open-

Implication for health policy/practice/research/medical education:

This paper aims to report a rare disease often undiagnosed due to lack of knowledge on the part of professionals, as well as demonstrating the risks, treatments available and patient outcomes.

ing of the anterior pericardium. A visual confirmation of was made, confirming that there was no pericardium on the left side, the heart was housed in the pleural cavity and the lung penetrated into the pericardial cavity (Figure 2). A neo pericardium with the use of three bovine pericardial patches® (Braile Biomedica - 18 * 12 cm), was confectioned. The patches were joined outside the operative field and anchored to the pleurae besides the posterior portion of the heart and remaining pericardium's anterior part.

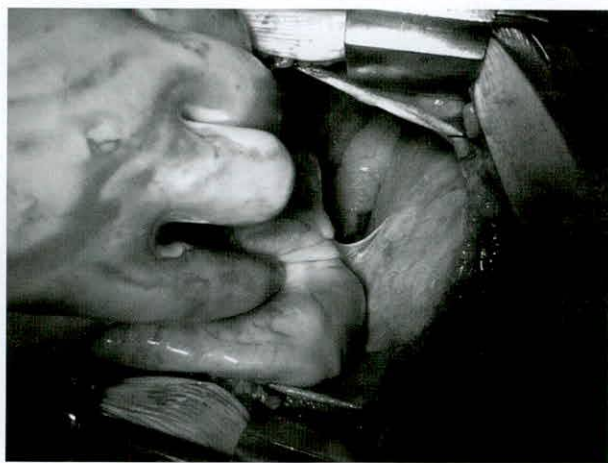

Figure 2. Surgical Aspect of Partial Agenesis of the Left Pericardium, Heart Rejected Earlier

After careful hemostasis, the thorax was closed and two drains were placed, one in the mediastinum and the other in left pleura, by different incisions. The patient was transferred to the ICU, where he had a good clinical evolution; drains were removed on the second postoperative day and the patient was discharged to the ward and home on the fourth day after surgery. A new MRI was performed on the third post-operative month, which showed normal cardiac function without any constriction caused to the heart, by the neo-pericardium (Figure 1B). The patient had an uneventful recovery with clinical controls performed 15 months postoperatively.

3. Discussion

Congenital absence of the pericardium is an anomaly caused by the persistence of the pleurapericardium foramen due to an abnormal development of pleuropericardial left membrane, caused by low blood flow to that structure. These changes generate premature atrophy of the common cardinal vein or duct of Cuvier, around the 5th to 6th week of pregnancy, resulting in these abnormality (1, 3, 4). This condition is rare, with about 400 cases reported in the literature (1). It is three times more common in men and in 70% to 80% of cases is limited to the left pericardium, being less frequent, agenesis of

the right pericardium (4% - 17%) and total agenesis (9%). Usually becomes asymptomatic and diagnosed on the basis of routine examinations. Among patients who have symptoms, the most common are asthenia, malaise, non-specific chest pain, dyspnea, syncope and dizziness. In addition, partial forms at risk of herniation of the left atrial appendage and/or ventricle may cause entrapment and death (2, 4).

Physical examination shows no specific signs, such as apical impulse displaced to the left in the total absence of the pericardium. The cardiac auscultation may reveal splitting of the second heart sound, ejectives basal murmurs and mesosystolic clicks accentuated during inspiration (3). The patient described, presented with dyspnea and chest pain, with no changes on the physical examination. As the clinical history and physical examination, laboratory tests such as ECG and echocardiography demonstrated indirect alterations but not specific. In the first one, the changes seen are sinus bradycardia, deviation of the electrical axis to the left, right bundle branch block and displacement of the transitional zone to the left - in patients with total agenesis, resulting from changes in the second position and abnormal cardiac motion, paradoxical movement of interventricular septum, dilated right heart chambers, hypermobility and anterior displacement of the posterior wall of the left ventricle during systole (3, 4).

Another exam, but less specific is the chest radiograph, which may show deviation of the cardiac silhouette to the left, the second arch prominence of the left border of the heart, the right cardiac border projecting over the column and the projection of the aortic arch and pulmonary trunk (4, 5). The most accurate exams are CT scan and MRI, of the chest, which visualize the parietal pericardium and the epicardial fat. Both techniques are able to confirm the diagnosis, assess the extent of injury and the presence of complications, being fundamental to plan therapy. Among the two, the RM has a better definition of soft tissue (2). Possible changes are characterized by the prominence of the left pulmonary artery, interposition of the lungs in the aorto-pulmonary window and the presence of sternoclavicular pericardial ligament (1, 2). In the case that reports the diagnosis was evidenced by MRI.

In addition to the complications of pericardial agenesis in about 30% - 50% of cases occur associations with other congenital anomalies such as patent ductus arteriosus, atrial septal defect, Fallot's tetralogy, mitral stenosis, bronchogenic cyst, pectus excavatum and congenital diaphragmatic hernia. Due to these associations, clinical finding of cardiopulmonary abnormality, in these patients is of a great importance, due to the fact that these changes are subject to surgical correction (1, 5).

Regarding therapy, there is currently no consensus, and the guidelines based on series of retrospective studies. In total agenesis cases, the risks of complications are

small, and non-surgical correction is indicated. Surgical treatment is reserved for symptomatic or asymptomatic patients with risk of atrial or ventricular herniation, as in extensive partial defects. The techniques available are: pericardioplasty with primary closure or reconstruction with synthetic materials, pericardiotomy, appendectomy and atrial enlargement, to reduce the risk of imprisonment, thus preventing the complications of this abnormality (1, 5). In this patient, based on the clinical presentation, surgical correction was performed, and after the procedure showed good performance, with improvement of its symptoms.

Acknowledgements

We thank the department head of cardiovascular surgery for their willingness to help build a case.

Authors' Contribution

All authors participated in the diagnosis and treatment of disease reported in addition to making the work.

Financial Disclosure

Costs for the production of the article were made by the authors.

Funding Support

The financing was conducted by the authors.

References

1. Verde F, Johnson PT, Jha S, Fishman EK, Zimmerman SL. Congenital absence of the pericardium and its mimics. *J Cardiovasc Comput Tomogr*. 2013;7(1):11-7.
2. Juarez AL, Akerstrom F, Alguacil AM, Gonzalez BS. Congenital partial absence of the pericardium in a young man with atypical chest pain. *World J Cardiol*. 2013;5(2):12-4.
3. Cucuini M, Lisi F, Consoli A, Mancini S, Bellino V, Galanti G, et al. Congenital defects of pericardium: case reports and review of literature. *Ital J Anat Embryol*. 2013;118(1):136-50.
4. Tomich J, Bhasin M, Philpott J. The role of cardiac magnetic resonance imaging in the evaluation of congenital pericardial defects. *Ann Thorac Surg*. 2013;95(6):2178-80.
5. Victor AR, Osorio P, Matos P, de Oliveira LM, Carrageta M. Congenital absence of left pericardium. *Rev Port Cardiol*. 2003;22(6):801-10.