

# Comparison Between Closed (Immediate Spica, Traction/Spica Cast) and Open Fixation (Plate Fixation) in Femoral Shaft Fractures in Children Below Nine Years Old Who Had Recoursed to Mashhad Imam Reza Hospital From 2002 to 2007

Hassan Rahimi<sup>1</sup>, Mohammad Gharehdaghi<sup>1\*</sup>, Ali Birjandinejad<sup>2</sup>, Masoud Mirkazemi<sup>2</sup>, Hamidreza Azimi<sup>3</sup>

<sup>1</sup>Orthopedic Research Center, Mashhad University of Medical Sciences, Mashhad, IR Iran

<sup>2</sup>Research and Education Department, Razavi Hospital, Mashhad, IR Iran

<sup>3</sup>Dental Research Center, Faculty of Dentistry, Mashhad University of Medical Sciences, Mashhad, IR Iran

\*Corresponding author: Mohammad Gharehdaghi, Orthopedic Research Center, School of Medicine, Mashhad University of Medical Sciences, Mashhad, IR Iran. Tel: +98-5118523300, Fax: +98-5118549234, E-mail: gharahdaghi@mums.ac.ir.

Received: August 29, 2013; Revised: October 10, 2013; Accepted: October 12, 2013

**Background:** Femur fracture is one of the most common fractures in children. Certain parameters such as the patient's age, the exact location of fracture, type of fracture, the mechanism of fracture, and the accompanying injuries determine which one of the many treatment techniques be used in each case.

**Objectives:** We aimed to compare the results of close and open techniques in pediatric femoral shaft fractures fixation (under 9 years old).

**Patients and Methods:** In this study, the clinical and radiologic results of the femur shaft fracture cases in children below 9 years old who recoured to Mashhad Imam Reza Hospital. Twenty six cases of femoral shaft fractures in 25 children (14 boys and 11 girls) which could be classified in three different classes; nine upper third (proximal) femoral shaft fractures, 14 middle third (midshaft) femoral fractures, three lower third (distal) femoral shaft fractures. Thirteen fractures (50%) were treated with immediate Spica cast, six fractures (23%) received traction and Spica cast, and surgical fixation with plate was carried out in the remaining seven cases.

**Results:** After a follow-up interval of at least 5 years, angle deformity was the most common complication observed in 32% of the studied patients. Limb length discrepancy and rotational deformity were observed in 24% and 16% of the cases. Treated with immediate Spica cast proved to have the highest complication prevalence of all (92.2%) and was followed by traction and Spica cast (83.4%) and were observed in patients' surgical fixation with plate (14.3%).

**Conclusion:** According to the results, internal fixation with plates can be considered an appropriate technique in cases of pediatric femoral shaft fractures.

**Keywords:** Femoral Fractures; Children; Fracture Fixation, Internal

## 1. Background

Generally, nonsurgical procedures are preferred over their surgical counterparts in treating pediatric fractures of which femoral shaft is of no exceptions. Via remodeling, child's bones transform from a weak porous tissue to the more solid lamellar structure. Increase in bone surface and diameter is mostly the result of the significant growth of the shaft cortex. This progressive increase in bone resistance can explain the bimodal distribution in femoral shaft fractures. In early childhood, femur is rather weak and may break after modest forces applied to the bone in routine activities. In adults, there's a different story; high energy trauma are necessary to provide forces strong enough to break the bone (1, 2).

Femoral shaft fractures, which include subtrochanteric and supracondylar fractures as well, are responsible for

1.6% of the total pediatric bone injuries. Male to female ratio is about 2.6 to 1 in femoral fracture cases, and the injury shows a bimodal distribution. The first peak in incidence is seen in early childhood, and the second one is observed in adolescence. In a study carried out in Marryland Hospital, a bimodal distribution with 2 and 12 years of age as its peaks was found in cases of femoral shaft fractures, and the pediatric annual incidence was estimated around 1/5000 (3).

Although very bothersome and unpleasant, femoral shaft fractures recovers with no significant complications in children. In the past, traction/cast was regarded as the standard treatment for femoral fractures and the patients needed a longer hospitalization for diagnosis. Nowadays, diverse techniques such as external fixation, compression plates, and rigid/flexible intramedullary

### Implication for health policy/practice/research/medical education:

Method of internal fixation with plaque in pediatric femur shaft fractures is an ideal and appropriate method for treatment.

Copyright © 2013, Razavi Hospital; Published by Kowsar Corp. This is an open-access article distributed under the terms of the Creative Commons Attribution License, which permits unrestricted use, distribution, and reproduction in any medium, provided the original work is properly cited.

nails are available; hence the decrease in treatment costs and complications (2).

Pediatric femoral fractures have different causes in different age classes. 80% of femoral fractures in children under the age of walking are caused by child abuse. In children less than 4 years old, up to 30% of femoral shaft fracture cases are due to child abuse (2). Treatment of pediatric femoral shaft fracture is usually age dependent and a significant overlap is seen among different age groups. Some parameters such as Body mass, bone age and the cause of trauma should be taken into consideration when selecting the treatment technique. It is estimated that nonsurgical methods cost 46% more than their surgical counterparts even if we consider the cost of a second surgery to remove fixation devices (1, 2). Initial Spica cast has the lowest cost. Skeletal traction and intramedullary nail are the two most expensive treatments.

## 2. Objectives

The aim of this study was to compare the results of close (immediate Spica cast, traction/Spica cast) and open (compression plates) techniques in pediatric femoral shaft fractures fixation (under 9 years old).

## 3. Patients and Methods

Twenty six fractures that were referred to Mashhad Imam Reza Hospital between 2002 to 2007 from the OR and the hospitals archives were enrolled in this descriptive study, in a 5-year follow-up period. Using the information from the archive, physical examination, and AP and lateral radiographs when they were coming to clinic for follow up. All the selected patients were investigated in the following parameters: age, gender, fracture location, displacement, limb short-age, initial angular deformity, limb discrepancy, limb length, internal and external rotation of femur of both legs, flexion and extension in hip and knee of both legs, treatment technique, and the parents satisfaction. It must be noted that all the studied cases were closed fractures.

## 4. Results

From the 26 fractures in 25 patients, 13 fractures (50%) had been treated with immediate Spica case, 6 (23%) fractures received an initial traction and a Spica cast for 12 to 20 days afterwards, and the remaining seven were

treated with DCP ( the plates had been removed 18 to 22 months after installation) (Figure 1).

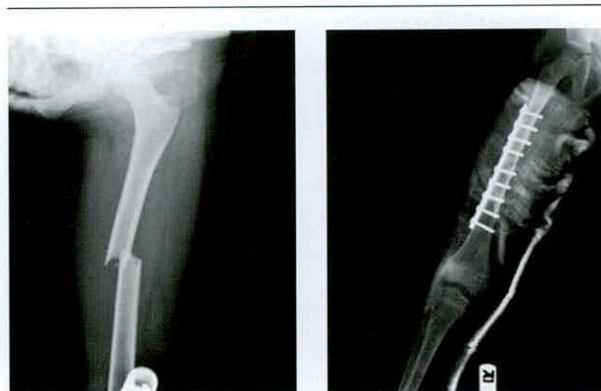

Figure 1. A Pair of Radiographs: Initial Referral and Post-Fixation

One of our patients was a known case of Osteogenesis Imperfecta with two femoral shaft fractures. The first fracture was located in the distal of right femur and had been treated with closed reduction and immediate Spica cast. Ten months later, he experienced the second fracture in the midshaft of his right femur and received an initial skeletal traction with consequent Spica cast for 12 days. In one of the patients who had been treated with traction/Spica cast method, cast had been removed due to the severe distal fragment angulations and had been replaced with a transtibial pin and a subsequent Spica cast, with the pin incorporated inside the cast. 14 out of our 25 cases were boys (56%). Out of the 26 fractures, 15 had occurred on the right (58%) and remaining 11 (42%) had fallen on the left.

In terms of location, the fractures could be divided to three categories:

Upper third (proximal) femoral shaft fractures, middle third (midshaft) femoral fractures, lower third (distal) femoral shaft fractures.

In our study, one case (4%), 16 cases (62%), and nine cases (34%) had been involved by proximal, midshaft, and distal femoral fractures, respectively.

Considering the complications of different fracture lines, the following could be said:

Out of the total of nine cases with transverse fracture lines, two cases (22.2%) had developed limb length discrepancy and three cases (33.3%) had developed angular deformity. The remaining four cases (44.4%) didn't show any complications (Table 1).

Table 1. The Distribution of Complications According to Femoral Shaft Fracture Lines in Children Under 9 Years Old

Fracture Line	Complication <sup>a</sup>		No Complication		SUM	
	Number	Percentage	Number	Percentage	Number	Percentage
Transverse	5	55.5	4	44.5	9	100
Spiral	9	64.3	5	35.7	14	100
Oblique	0	0	3	100	3	100

<sup>a</sup> Complication include LLD, rotation deformity, varus/valgus deformity.

Out of the total 14 cases with spiral fracture lines, four cases (28.6%) showed limb discrepancy and five cases (35.7%) had developed angle deformity. No complications were observed in the remaining five cases. In patients with oblique fracture lines no complications were observed. From a total of nine patients with distal femoral fractures, three cases (33.3%) had developed limb length discrepancy, three cases (33.3%) had developed angle de-

formity and two cases (22.2%) showed rotational deformity. In one cases (11.1%) no complications were recorded (Table 2) (Figure 2).

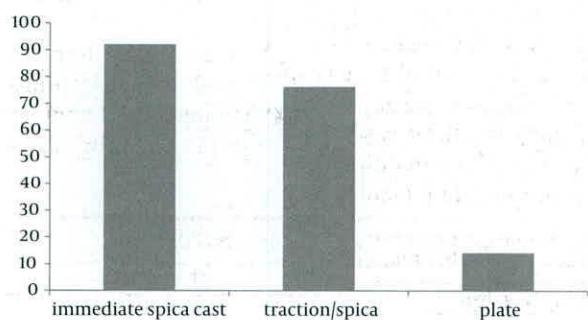
In the patients treated with traction/Spica cast, three cases (50%) showed angle deformity and one case (16.6%) had developed rotation deformity. In the patient treated with Plate, no angle deformity was observed (Table 3) (Figure 3).

**Table 2.** The Distribution of Complications According to the Fracture Location

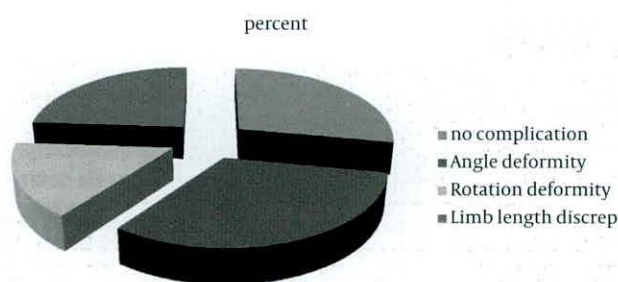
Fracture Location	Complication		No Complication		SUM	
	Number	Percentage	Number	Percentage	Number	Percentage
Upper third	0	0	1	100	1	100
Middle third	4	25	12	75	16	100
Lower third	8	88.9	1	11.1	9	100

**Table 3.** The Distribution of Complications in Different Techniques Used in Femoral Shaft Fractures of Children Below 9 Years Old

Technique Complication	Closed				Open	
	Immediate Spica Cast		Traction/Spica Cast		Compression Plate	
	Number	Percentage	Number	Percentage	Number	Percentage
Limb shortage > 2 cm	2	15.4	0	0	0	0
Excessive limb growth	3	23	1	16.6	0	0
Knee flexion limitation	0	0	0	0	0	0
Knee extension limitation	0	0	0	0	0	0
Rotation deformity	3	23	1	16.6	0	0
Varus/valgus	4	30.8	3	50	1	14.3
Delayed union	0	0	0	0	0	0
Non-union, more than 3 months	0	0	0	0	0	0
Infection	0	0	0	0	0	0
Muscular weakness	0	0	0	0	0	0
Neurovascular lesion	0	0	0	0	0	0
No complication	1	7.8	1	16.6	6	85.7
<b>Total</b>	<b>13</b>	<b>100</b>	<b>6</b>	<b>100</b>	<b>7</b>	<b>100</b>



**Figure 2.** The Distribution of Complications in Different Femoral Shaft Fractures Treatment Techniques in Children Under 9 Years Old



**Figure 3.** The Distribution of Complications in Treated Femoral Shaft Fractures in Children Under 9 Years

## 5. Discussion

In this study, 56% of the patients are male and 44% of the patients are females. Male to female ratio is about 1.3 to 1 which clearly shows the higher prevalence in males. This finding is consistent with the published results in the credible scientific resources. There is a significant difference between the reported male to female ratio in the textbooks (2.6 to 1) and our findings (1.3 to 1), which can be attributed to sample scarcity. In our study, the highest prevalence of femoral shaft fractures were seen in children under 2 years old (46%), which is comparable to the other studies reported value of below 3 years old (4); parental neglect and less bone resistant observed in this age class may be responsible for this fact. Angle deformity comprises the most commonly observed complication in our study (32%), whereas limb length discrepancy has been reported as the main complication in the textbooks (2, 3). Limb shortage with a range of five to 10 millimeters were observed in 15.4% of the patients treated with immediate Spica cast in this study, which didn't prove of significance in terms of aesthetics and appearance. According to the references, in limb shortages above 3 cm subsequent to Spica cast, cast removal should be carried out and the patient should be treated with traction until the acceptable limb length is achieved; A second spica cast will be applied afterwards (4, 5).

Numerous techniques have been proposed for internal fixation in cases of pediatric femoral shaft fractures. In our study, no limb shortage above 2 cm was observed in cases treated with internal plate's techniques. This is comparable to the results of James and colleagues study in 2000 in who investigated internal fixation techniques for femoral shaft fractures and reported limb shortage in 25% of the patients. All things considered, it seems as if limb shortage is less common in plate fixation when compared to other internal fixation techniques (6-8). According to the same study, femoral fractures in the distal third were accompanied by complications (limb shortage/excessive growth) most frequently (88.9%), which is similar to the results of some other peer studies (1-3, 9).

In terms of fracture line, spiral fracture proved to have the highest complication prevalence of all (64.3%) and was followed by transverse fracture (55.5%). No complications were observed in patients with oblique fractures. These differences can be a result of the different energy in each injury. Similar studies and reference textbooks have reported highest complication prevalence in spiral fractures which is consistent with our results. This is not the case with oblique fractures, which have been reported to be accompanied by several complications in the related literature. This difference in this aspect can be attributed to sample scarcity, and more extensive studies are needed

to achieve a more precise conclusion.

Over all based on this study the risk of malunion and other related complications are not seen in open reduction and plate fixation for pediatric femoral shaft fracture, on the other hand the severe surgical complications are so rare. In fact open reduction and plate fixation now is our preferred method.

## Acknowledgements

The authors thank the Vice Chancellor for Research of Mashhad University of Medical Sciences for funding and supports.

## Authors' Contribution

Study concept and design: Hassan Rahimi Shorin, Mohammad Ghare Daghi, and Ali Birjandinejad. Analysis and interpretation of data: Hamidreza Azimi, and Masoud Mirkazemi. Drafting of the manuscript: Masoud Mirkazemi and Ali Birjandinejad. Critical revision of the manuscript for important intellectual content: Mohammad Ghare Daghi, Hamidreza Azimi, and Hassan Rahimi Shorin.

## Financial Disclosure

Authors have no financial interests.

## Funding Support

This study was supported in part by Vice Chancellor of research, Mashhad University of medical sciences.

## References

1. Wood GW, Whittle AP. Fractures of lower extremity. In: Canale ST. *Campbell's operative orthopaedics*. 10 ed. Philadelphia: Mosby; 2003. p. 2825-2859.
2. Kimura DH, Phillips SJ. Femoral shaft fractures. In: Kasser JR, Beaty JH s. *Rockwood and wilkin's fractures in children*. 5 ed. Philadelphia: LWW; 2001. p. 914-980.
3. Millares M. Fracture and dislocation in children. In: Canale ST. *Campbell's operative orthopaedics*. 10 ed. Philadelphia: Mosby; 2003. p. 1504-1516.
4. Berne D, Mary P, Damsin JP, Filipe G. [Femoral shaft fracture in children: treatment with early spica cast]. *Rev Chir Orthop Reparatrice Appar Mot*. 2003;**89**(7):599-604.
5. Lee YH, Lim KB, Gao GX, Mahadev A, Lam KS, Tan SB, et al. Traction and spica casting for closed femoral shaft fractures in children. *J Orthop Surg (Hong Kong)*. 2007;**15**(1):37-40.
6. Bar-On E, Sagiv S, Porat S. External fixation or flexible intramedullary nailing for femoral shaft fractures in children. A prospective, randomised study. *J Bone Joint Surg Br*. 1997;**79**(6):975-8.
7. Wright JG. The treatment of femoral shaft fractures in children: a systematic overview and critical appraisal of the literature. *Can J Surg*. 2000;**43**(3):180-9.
8. Parsch KD. Modern trends in internal fixation of femoral shaft fractures in children. A critical review. *J Pediatr Orthop B*. 1997;**6**(2):117-25.
9. Flynn JM, Skaggs DL, Sponseller PD, Ganley TJ, Kay RM, Leitch KK. The surgical management of pediatric fractures of the lower extremity. *Instr Course Lect*. 2003;**52**:647-59.