

Evaluation of PPAR- α Agonist effect on Kidney Performance Through Increment of Nitric Oxide During Hyperglycemia-Induced Nephropathy in Rat

Habib Yaribeygi,¹ and Mohammad Taghi Mohammadi^{1*}

¹Department of Physiology and Biophysics, School of Medicine, Baqiyatallah University of Medical Sciences, Tehran, IR Iran

* Corresponding author: Mohammad Taghi Mohammadi, Department of Physiology and Biophysics, School of Medicine, Baqiyatallah University of Medical Sciences, Tehran, IR Iran. Tel/Fax: +98-2126127257; +98-9127713583, Fax: +98-2126127257, E-mail: Mohammadi.mohammadt@yahoo.comMohammadimohammadt@bmsu.ac.ir

Received 2016 March 07; Revised 2016 April 10; Accepted 2016 April 25.

Abstract

Background: Chronic uncontrolled hyperglycemia is the common reason of renal failure.

Objectives: We aimed to assess the possible protective effects of PPAR- α agonist (fenofibrate) on kidney performance and nitric oxide (NO) level of kidney in experimental model of diabetic nephropathy (DN).

Materials and Methods: Male Wistar rats were randomly divided into four groups (n = 6); Normal, Normal treatment, Diabetic and Diabetic treatment. Rats were made diabetic by an intravenous injection of streptozotocin (40 mg/kg). After 72 hours, blood samples were collected for approving diabetes and the rats with blood glucose above 400 mg/dL were considered as diabetic animals. Treated groups received orally fenofibrate for 8 weeks (80 mg/kg/day). At the end, blood samples were collected for measuring blood glucose and creatinine. Finally, NO content and histopathological assessments of kidney were assessed at termination of experiment.

Results: Fenofibrate did not change the blood glucose of normal or diabetic rats. Diabetes increased the proteinuria (82%) and blood creatinine of diabetic rats (4.51 ± 0.45 mg/dL) compared to normal rats (0.66 ± 0.14 mg/dL). Chronic hyperglycemia also decreased the content of renal NO (37%) compared with normal rats in accompany with histopathological damages. Fenofibrate significantly decreased the proteinuria (80%) and blood creatinine of diabetic rats (1.66 ± 0.23 mg/dL). The content of NO increased in the kidney of both treated rats (31%). Fenofibrate also improved the histopathological changes of diabetic kidney.

Conclusions: Our findings indicate that fenofibrate (PPAR- α agonist) is able to prevent DN progression and improve kidney performance during chronic uncontrolled hyperglycemia possibly through increase in NO bioavailability of kidney.

Keywords: Nitric Oxide, Nephropathy, PPAR- α Agonist, Fenofibrate, Diabetes Mellitus

1. Background

Diabetic nephropathy (DN) is the main cause of renal failure worldwide. It is estimated that about forty percent of diabetic patients suffer from nephropathy (1). Based on amount of protein excretion in urine (proteinuria), DN is divided into two forms; incipient (onset of DN) and overt (2). High proteinuria is the main marker of overt form of DN that is usually accompanied by hypertension (2). It is thought that DN be a microvascular problem that damages many various cellular elements of kidney such as podocytes, mesangial cells and tubular epithelia (1, 2). These injuries have a major impact on renal functions leading to visible changes in renal excretion of metabolic substance (2). Any change of renal function rapidly changes the plasma contents of creatinine and protein, which in turn have negative effect on the quality of patient's life (3, 4).

Recent findings are suggesting that the numerous pathways are activated during DN including hemody-

namic pathways, inflammatory cytokines and oxidative stress mediators (3, 5). These pathways individually or cooperatively play a crucial role in induction and progression of DN. One of the most important renal vascular modulators is nitric oxide (NO), which correlates with progression of DN (6). In renal vascular bed, NO has an important role in modifying vascular tone and can adjust some major factors such as glomerular filtration rate (GFR) and renal plasma flow (RPF) (4). Based on previous findings, lack of NO and reduction of its bioavailability can result in deficiency of renal functions (7). It is reported that severely endothelial dysfunction, which is seen in diabetes, decreases NO formation of renal microvascular bed (8). This reduction during diabetes leads to rising of uncoupled vascular endothelial growth factor (VEGF) in accompany with matrix expansion (9). Also, some studies have shown that inhibition of NOS (NO synthase) can lead to severe vascular problems with increasing VEGF expression in renal vessels (10, 11). Likewise, Nakagawa et al. showed that diabetic

eNOS (endothelial NOS) knockout mice develop more advanced DN (7). Additionally, Cheng et al. reported that improvement of eNOS activity retarded the progression of DN in db/db. mice (12).

Previous findings have demonstrated that peroxisome proliferator activated receptor alpha (PPAR- α) agonists, which act as transcription factors, are able to modulate the symptoms of DN (13). Park et al. reported that the mice lacking PPAR- α genes showed more renal damages during DN (14). Other studies have reported that fenofibrate was able to attenuate the renal injuries in diabetic states (14,15). Fenofibrate is a member of PPAR- α agonists and acts as a transcription factor in intracellular space (13). Li et al. also indicated that fenofibrate declined the tubulointerstitial fibrosis and inflammation in rat model of DN (15). Moreover, Kostapanos et al. reported that fenofibrate could improve many DN criteria (albuminuria and glomerular lesions) in mice model of DN via its hypolipidemic and anti-inflammatory effects (13). However, there is no document about the effects of fenofibrate on NO level of renal tissue during DN.

2. Objectives

Since the content of renal NO decreases during uncontrolled diabetes and PPAR- α agonists have protective effects in diabetic states, we aimed to examine the possible protective effects of fenofibrate on kidney performance and NO level of kidney in experimental model of DN.

3. Materials and Methods

The study was done in Baqiyatallah University of Medical Sciences (Faculty of Medicine, Department of Physiology and Biophysics) in summer of 2015. In the present study (experimental-interventional), male Wistar rats (220 - 250 g) were kept in standard polyester cages (2 rats in each cage) in a room with standard temperature ($22 \pm 2^\circ\text{C}$) and humidity ($55 \pm 5\%$) with 12 hours light/dark cycle and free access to water and standard rodent chow. All protocols of the study were approved by the institutional animal ethics committee of Baqiyatallah University of Medical Sciences, which follows the NIH Guidelines for care and use of animals.

Twenty four normal rats (blood glucose was 120 ± 30 mg/dL) were randomly divided into four groups ($n = 6$); Normal, Normal treatment, Diabetes, and diabetic treatment. Diabetes was induced by an intravenous injection of streptozotocin (Sigma, USA), (40 mg/kg) that dissolved in cold saline. The non-diabetic rats were received this

solution in the same volume. 72 hours later, blood samples were obtained from rat's tail and used for monitoring blood glucose by glucometer. The rats with blood glucose between 400 and 500 mg/dL were considered as diabetic animals and then randomly divided into two diabetic groups. Also, treated animals were orally received fenofibrate (80 mg/kg/day) for 8 weeks. Treatment was performed via intra-gastric gavage.

Blood samples were taken from rat's tail to assay the plasma glucose and creatinine at the beginning (5 days after injection of STZ) and termination of experiment. Plasma was separated by centrifugation of the blood samples at 3000 rpm for 15 minutes. Then, the concentration of the plasma glucose and creatinine were determined by using available commercial kit (Pars-Azmon, Iran). At the end of experiment, the urine samples were collected by metabolic cage for 24 hours and the content of urine protein (mg/24 hours) was measured by using available commercial kit (Pars-Azmon, Iran). At the end, the rats were sacrificed under deep anesthesia to remove kidney for assessment of nitrate (NOx) content and histopathological changes.

3.1. Nitrate (NOx) Assay

The fractions of thawed samples were weighed and homogenization medium (phosphate buffer, 0.1 mol, pH 7.4) were added to them. After homogenizing of tissues on ice by electric homogenizer, samples were centrifuged (20 minute at 4°C and 4000 rpm) and supernatant was removed as the renal cytosolic extract and stored in -80°C for analysis of NOx content.

The NOx in the 'cytosolic extract' was measured by the colorimetric reaction of the Griess reagent. 0.1 mL of cytosolic extract was deproteinized by adding 0.2 mL of zinc sulfate solution and centrifuged for 20 minute at 4000 rpm and 4°C to separate supernatant for NOx assay. 0.1 mL of supernatant (as sample) or pure water (as blank) or sodium nitrate (as standard) was mixed with 0.1 mL vanadium III chloride to reduce nitrate to nitrite. 0.05 mL sulfanilamide (0.01 %) and 0.05 mL N-[1-naphthyl] ethylenediamin dihydrochloride (NED, 0.01 %) were incubated for 30 minute in dark place at 37°C . Finally, the absorbance of solution was determined at wave length of 540 nm. Nitrite concentration was estimated from a standard curve generated from the absorbance of each sodium nitrate solution. Finally, the nitrite-nitrate levels were expressed as $\mu\text{g}/\text{mg}$ protein (16).

Protein content in the cytosolic extracts was determined with Bradford method by spectrophotometrically at wave length of 595 nm. Bovine serum albumin was used as a standard and concentration of protein was expressed

as mg/ml and amount of NOx in each sample were normalized to the cytosolic protein concentration and the results were expressed as $\mu\text{g}/\text{mg}$ of the cytosolic protein ($\mu\text{g}/\text{mg}$ protein) (17).

3.2. Histological Assessment

At the end of the experiment, animals were sacrificed under deep anesthesia. The kidneys were removed and fixed in formalin (10%) for two weeks. After fixation and tissue processing, coronal serial sections ($5\ \mu\text{m}$ in thickness) were prepared for conventional histological examination. Paraffin embedded sectioning (each $50\ \mu\text{m}$ intervals) was processed routinely for hematoxylin and eosin (H & E) staining. After staining procedure, sections were dehydrated with administration of 70, 80, 96, 100, and 100% ethanol, respectively. The samples were placed in xylene solution for two times (each time was 15 minutes) owing to clearing. Due to mounting, the samples were covered with entelan sticker and then lamels were placed on them. The histological changes were observed (by a pathologist) through a light microscope (Nikon, Japan) connected to digital camera (CMEX, Holland) for capturing the micrographs.

3.3. Statistical Analyses

The results were expressed as the mean \pm SD. All statistical comparisons were done using one way analysis of variance (ANOVA) and Tukey post-hoc test. Also, paired t-test was used to determine the differences between the data of beginning and termination of experiment. In all states $P < 0.05$ was considered as significant difference.

4. Results

4.1. Effect of Fenofibrate on Plasma Glucose and Creatinine

Table 1 shows the representative changes of plasma glucose and creatinine (mg/dL) for different groups of the experiment. The mean value of plasma glucose in normal rats was $< 150\ \text{mg}/\text{dL}$ at the beginning and termination of experiment. Fenofibrate administration did not change the plasma glucose of normal treated rats. Induction of diabetes in diabetic group significantly increased the value of plasma glucose at the beginning and termination of experiment ($> 400\ \text{mg}/\text{dL}$). Administration of fenofibrate for eight weeks did not change the plasma glucose of diabetic treated rats.

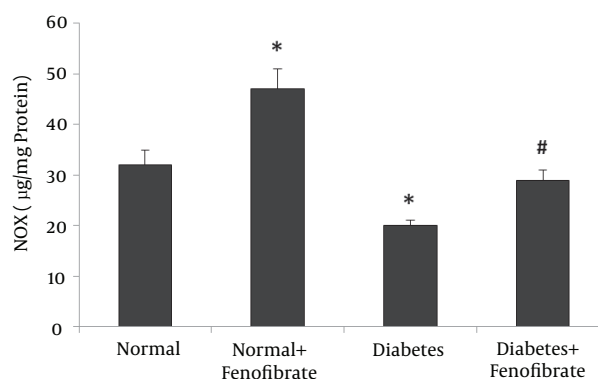
The mean value of plasma creatinine in normal rats was $< 1\ \text{mg}/\text{dL}$ at the beginning and termination of experiment. Fenofibrate administration did not change the plasma glucose of normal treated rats. Induction of diabetes in diabetic group significantly increased the value of

plasma creatinine at the termination of experiment ($4.51 \pm 0.45\ \text{mg}/\text{dL}$), ($P < 0.01$). Administration of fenofibrate for eight weeks significantly decreased the plasma creatinine of diabetic treated rats ($1.66 \pm 0.23\ \text{mg}/\text{dL}$) compared to the diabetic non-treated rats ($P < 0.05$).

4.2. Effect of Fenofibrate on Nitrate (NOx) Content of Kidney

Figure 1 shows the NOx content of kidney in different experimental groups after eight weeks. The content of NOx in normal group was $32 \pm 3\ \mu\text{g}/\text{mg}$ protein and fenofibrate administration significantly increased the content of NOx in normal treated rats ($47 \pm 4\ \mu\text{g}/\text{mg}$ protein), ($P < 0.01$). Induction of diabetes significantly decreased the NOx content of kidney ($20 \pm 1\ \mu\text{g}/\text{mg}$ protein), ($P < 0.01$), whereas treatment with fenofibrate significantly increased it ($29 \pm 2\ \mu\text{g}/\text{mg}$ protein), ($P < 0.05$).

Figure 1. Effect of PPAR- α Agonist (Fenofibrate) on Nitrate (NOx) Content (mg/ μg Protein) at the End of Experiment



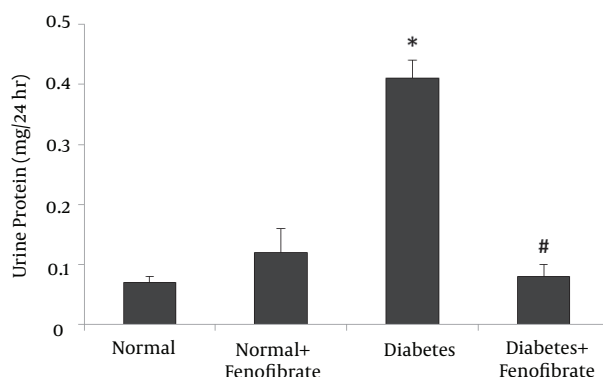
All values are presented as mean \pm SD. *Significantly different from normal group ($P < 0.01$), #significantly different from diabetes group ($P < 0.05$).

4.3. Effect of Fenofibrate on Urine Protein

As shown in Figure 2, the content of urine protein excretion (mg/24 hours) was low in both normal ($0.07 \pm 0.01\ \text{mg}/24\ \text{hours}$) and normal treated rats ($0.12 \pm 0.04\ \text{mg}/24\ \text{hours}$). There was no significant difference in urine protein value between them. The content of urine protein excretion markedly increased in diabetic rats ($0.41 \pm 0.03\ \text{mg}/24\ \text{hours}$) compared with normal group ($P < 0.01$). After treatment with fenofibrate for 8 weeks, the content of urine protein excretion (proteinuria) significantly reduced in diabetic treated rats ($0.08 \pm 0.02\ \text{mg}/24\ \text{hours}$) compared with non-diabetic treated rats ($P < 0.01$).

Table 1. Representative Changes of Plasma Glucose and Creatinine at the Beginning and Termination of Experiment^a

Groups	Blood Glucose, mg/dL		Blood Creatinine, mg/dL	
	Day 1	Day 56	Day 1	Day 56
Normal	107 ± 9	96 ± 18	0.63 ± 0.17	0.66 ± 0.14
Normal + Fenofibrate	109 ± 9	106 ± 10	0.81 ± 0.17	0.78 ± 0.12
Diabetes	449 ± 35 ^b	422 ± 23 ^b	0.92 ± 0.16	4.51 ± 0.45 ^b
Diabetes + Fenofibrate	415 ± 25 ^b	409 ± 30 ^b	1.00 ± 0.23	1.66 ± 0.23 ^c

^aValues are expressed as mean ± SD.^bSignificantly different from normal group ($P < 0.01$).^cSignificantly different from diabetes group ($P < 0.05$).**Figure 2.** Effect of PPAR- α Agonist (Fenofibrate) on Urine Protein Excretion (mg/24 Hours) at the End of Experiment

All values are presented as mean ± SD. *Significantly different from normal group ($P < 0.01$), #significantly different from diabetes group ($P < 0.01$).

4.4. Effect of Fenofibrate on Histological Changes

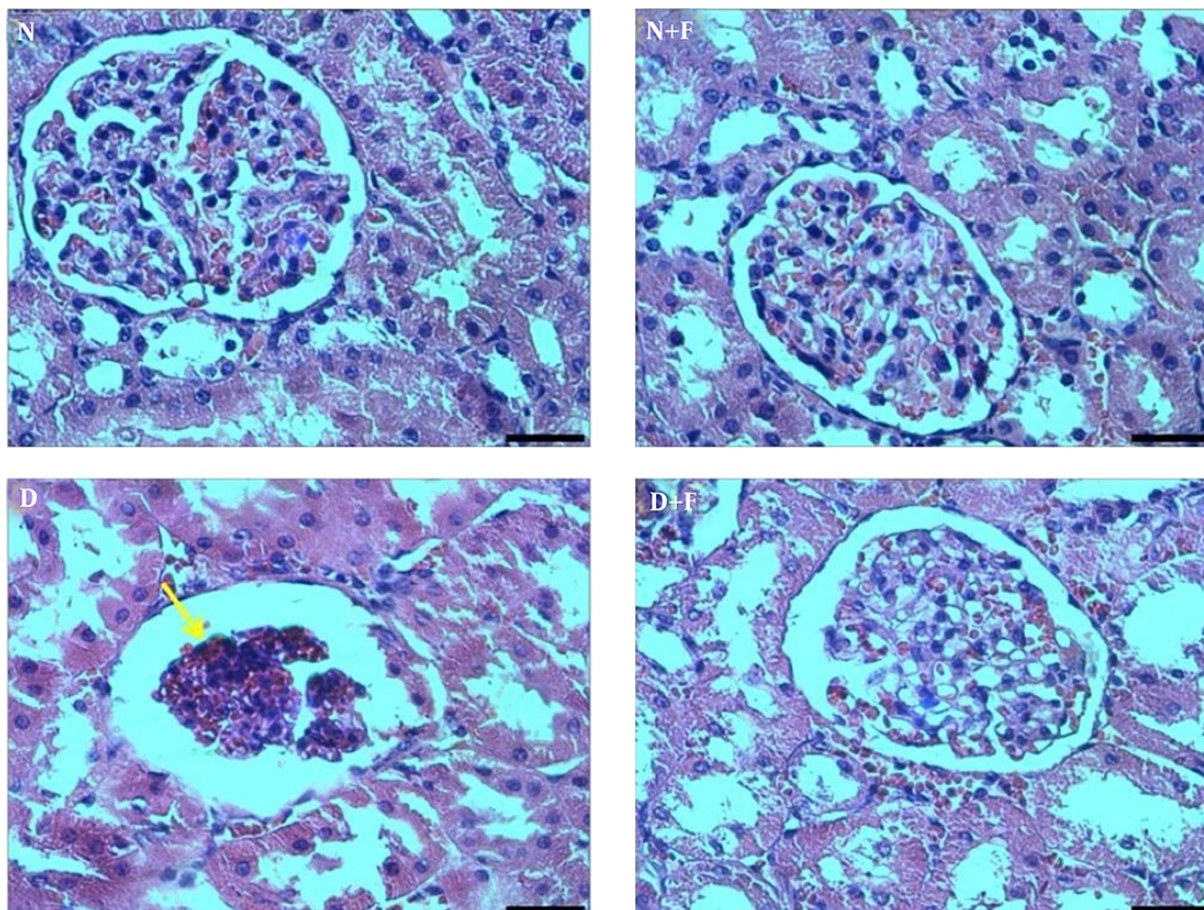
As demonstrated in Figure 3 the glomeruli are in normal state in normal and normal treated rats. In histopathological assessments, we did not observe any morphological damages in the kidneys of normal and normal treated rats. The destroyed glomeruli and glomerulosclerosis were clearly observed in the kidney of diabetic rats. However, these morphological changes were not seen in the kidney of diabetic treated rats with fenofibrate.

5. Discussion

Previous studies have shown that a decrease in NO bioavailability has a crucial role in progression of DN (6, 18). The findings of present study indicated that NO content of kidney decreased during chronic uncontrolled hyperglycemia in accompany with alterations of kidney functions (increment of blood creatinine and urinary protein excretion). According to our results, normal and diabetic

rats treated with fenofibrate (PPAR- α agonist) showed a significant increase in NO content of kidney and also improvement of renal functions in diabetic states. Likewise, fenofibrate reduced hyperglycemia-induced histopathological damages of kidney.

Increment of blood glucose is the main marker of diabetes mellitus. In the present study, type I diabetes was used for induction of chronic hyperglycemia. However, fenofibrate administration could not change the blood glucose of diabetic or normal treated rats. These findings are in agreement with the findings of Li et al. (15). Therefore, it is concluded that PPAR- α agonist (fenofibrate) has no effect on the blood glucose of diabetic or normal states. Our findings also indicated that blood creatinine increased by chronic hyperglycemia in diabetic rats. Creatinine is a by-product of muscle metabolism and rising of its concentration is the main sign of GFR reduction (19). In advance stages of DN, GFR is declined due to hemodynamic changes. So the clearance of creatinine is damaged and its concentration increases in plasma (20). Proteinuria also is the main symptom of DN that appeared in diabetic rats. This Phenomenon occurs mainly due to damage to filtration barrier during diabetic states (21). Furthermore, structural changes in the kidney like glomerulosclerosis results in proteinuria that appeared in the kidney of diabetic rats. Based on previous studies, overproduction of advanced glycation end products (AGEs), overexpression of transforming growth factor β (TGF- β) and activation of inflammatory pathways have crucial roles in developing of DN (1). Also, overproduction of different free radicals and oxidative damage during diabetes is the main reason of damage to the filtration barrier (22). Our findings indicated that fenofibrate attenuated the plasma concentration of creatinine and proteinuria. Also, fenofibrate improved the histopathological damages (injury to glomeruli and glomerulosclerosis) of kidney in diabetic treated rats. Previous studies have shown that fenofibrate was able to attenuate the AGEs production during diabetic

Figure 3. Micrographs (H & E Staining Method) Show the Histopathological Damages of Kidney at the End of Experiment in Diabetic Rats (D)

Diabetic rats treated with fenofibrate (D + F) showed less morphological damages such as destroyed glomeruli compared to non-treated diabetic rats. Normal (N) and normal treated rats with fenofibrate (N + F) did not show morphological damages, (400 X, Scal bar; 30 μ m).

states (23). Reported, this agonist has inhibited the different inflammatory pathways, which involve in DN progression (24). Additionally, Rosenson et al. reported that fenofibrate ameliorated oxidative stress and the inflammatory response in subjects with hypertriglyceridemia and the metabolic syndrome (25). Therefore, it is suggested that treatment with fenofibrate in diabetic rats has attenuated the progression of DN possibly through reduction of AGEs products, free radicals and inflammatory mediators.

It has been reported that NO bioavailability is decreased during DN (5, 18). Previous findings have reported that diabetic eNOS (endothelial NOS) knockout mice develop advanced DN (7), and improvement of eNOS activity retards the progression of DN (12). In the present study, we showed that the index of kidney NO (nitrate content) decreased in accompany with DN symptoms in diabetic rats. Since the type-1 diabetes was used in this study and the role

of insulin in eNOS activity has been confirmed (26), we concluded that reduction of insulin was the main reason of NO decrement. Moreover, diabetes can increase the Rho Kinase activity, which is a suppressor of eNOS expression and so leads to lower NO bioavailability (23). As we found the reduction of renal NO during diabetes, we concluded that the reduction of NO bioavailability had crucial role in development of DN. The findings of present study indicated that fenofibrate in both normal and diabetic treated rats increased the NO content of kidney concomitant decrease in DN symptoms. In agreement with our findings, Goya et al. demonstrated that PPAR- α agonists increase the NOS expression in vascular endothelial cells of systemic circulation and enhance the eNOS activity, which results in an increment of NO bioavailability (27). Since the DN symptoms decreased in accompany with increment of NO bioavailability and additionally the crucial role of NO deficiency in

the progression of DN has been proven, we concluded that fenofibrate has decreased the progression of DN possibly through increment of NO bioavailability. However, more research needs to clarify the direct effects of PPAR- α agonist on the NOS activity or expression during normal or diabetic states.

In conclusion, our findings indicated that administration of fenofibrate (PPAR- α agonist) during chronic uncontrolled hyperglycemia is able to prevent DN. It is appeared that fenofibrate improves renal performance and decreases DN symptoms possibly through an increase in NO bioavailability of kidney.

Acknowledgments

The authors are cordially appreciating the financial support of vice chancellor for research of Baqiyatallah University of Medical Sciences, Tehran, Iran.

References

1. Navarro-Gonzalez JF, Mora-Fernandez C, Muros de Fuentes M, Garcia-Perez J. Inflammatory molecules and pathways in the pathogenesis of diabetic nephropathy. *Nat Rev Nephrol*. 2011;7(6):327-40. doi: [10.1038/nrneph.2011.51](#). [PubMed: [21537349](#)].
2. Fraser DJ, Phillips AO. Diabetic nephropathy. *Medicine*. 2007;35(9):503-6. doi: [10.1016/j.mpmed.2007.06.007](#).
3. Tavafi M. Diabetic nephropathy and antioxidants. *J Nephropathol*. 2013;2(1):20-7. doi: [10.5812/nephropathol.9093](#). [PubMed: [24475422](#)].
4. Jerums G, Premaratne E, Panagiotopoulos S, Clarke S, Power DA, MacIsaac RJ. New and old markers of progression of diabetic nephropathy. *Diabetes Res Clin Pract*. 2008;82 Suppl 1:S30-7. doi: [10.1016/j.diabres.2008.09.032](#). [PubMed: [18937992](#)].
5. Arora MK, Singh UK. Molecular mechanisms in the pathogenesis of diabetic nephropathy: an update. *Vascul Pharmacol*. 2013;58(4):259-71. doi: [10.1016/j.vph.2013.01.001](#). [PubMed: [23313806](#)].
6. Veelken R, Hilgers KF, Hartner A, Haas A, Bohmer KP, Sterzel RB. Nitric oxide synthase isoforms and glomerular hyperfiltration in early diabetic nephropathy. *J Am Soc Nephrol*. 2000;11(1):71-9. [PubMed: [10616842](#)].
7. Nakagawa T, Sato W, Glushakova O, Heinig M, Clarke T, Campbell-Thompson M, et al. Diabetic endothelial nitric oxide synthase knockout mice develop advanced diabetic nephropathy. *J Am Soc Nephrol*. 2007;18(2):539-50. doi: [10.1681/ASN.2006050459](#). [PubMed: [17202420](#)].
8. Brodsky SV, Gao S, Li H, Goligorsky MS. Hyperglycemic switch from mitochondrial nitric oxide to superoxide production in endothelial cells. *Am J Physiol Heart Circ Physiol*. 2002;283(5):H2130-9. doi: [10.1152/ajpheart.00196.2002](#). [PubMed: [12384491](#)].
9. Da Silva-Azevedo L, Baum O, Zakrzewicz A, Pries AR. Vascular endothelial growth factor is expressed in endothelial cells isolated from skeletal muscles of nitric oxide synthase knockout mice during prazosin-induced angiogenesis. *Biochem Biophys Res Commun*. 2002;297(5):1270-6. [PubMed: [12372425](#)].
10. Kang DH, Nakagawa T, Feng L, Johnson RJ. Nitric oxide modulates vascular disease in the remnant kidney model. *Am J Pathol*. 2002;161(1):239-48. doi: [10.1016/S0002-9440\(10\)64175-2](#). [PubMed: [12107108](#)].
11. Zhao Q, Egashira K, Inoue S, Usui M, Kitamoto S, Ni W, et al. Vascular endothelial growth factor is necessary in the development of arteriosclerosis by recruiting/activating monocytes in a rat model of long-term inhibition of nitric oxide synthesis. *Circulation*. 2002;105(9):1110-5. [PubMed: [11877364](#)].
12. Cheng H, Wang H, Fan X, Pauksakon P, Harris RC. Improvement of endothelial nitric oxide synthase activity retards the progression of diabetic nephropathy in db/db mice. *Kidney Int*. 2012;82(1):1176-83. doi: [10.1038/ki.2012.248](#). [PubMed: [22785174](#)].
13. Kostapanos MS, Florentin M, Elisaf MS. Fenofibrate and the kidney: an overview. *Eur J Clin Invest*. 2013;43(5):522-31. doi: [10.1111/eci.12068](#). [PubMed: [23480615](#)].
14. Park CW, Kim HW, Ko SH, Chung HW, Lim SW, Yang CW, et al. Accelerated diabetic nephropathy in mice lacking the peroxisome proliferator-activated receptor alpha. *Diabetes*. 2006;55(4):885-93. [PubMed: [16567507](#)].
15. Li L, Emmett N, Mann D, Zhao X. Fenofibrate attenuates tubulointerstitial fibrosis and inflammation through suppression of nuclear factor-kappaB and transforming growth factor-beta1/Smad3 in diabetic nephropathy. *Exp Biol Med (Maywood)*. 2010;235(3):383-91. doi: [10.1258/ebm.2009.009218](#). [PubMed: [20404057](#)].
16. Rolo AP, Palmeira CM. Diabetes and mitochondrial function: role of hyperglycemia and oxidative stress. *Toxicol Appl Pharmacol*. 2006;212(2):167-78. doi: [10.1016/j.taap.2006.01.003](#). [PubMed: [16490224](#)].
17. Bradford MM. A rapid and sensitive method for the quantitation of microgram quantities of protein utilizing the principle of protein-dye binding. *Anal Biochem*. 1976;72:248-54. [PubMed: [942051](#)].
18. Baylis C. Nitric oxide deficiency in chronic kidney disease. *Am J Physiol Renal Physiol*. 2008;294(1):F1-9. doi: [10.1152/ajprenal.00424.2007](#). [PubMed: [17928410](#)].
19. Perrone RD, Madias NE, Levey AS. Serum creatinine as an index of renal function: new insights into old concepts. *Clin Chem*. 1992;38(10):1933-53. [PubMed: [1394976](#)].
20. Ruggenenti P, Gaspari F, Perna A, Remuzzi G. Cross sectional longitudinal study of spot morning urine protein:creatinine ratio, 24 hour urine protein excretion rate, glomerular filtration rate, and end stage renal failure in chronic renal disease in patients without diabetes. *BMJ*. 1998;316(7130):504-9. [PubMed: [9501711](#)].
21. Warram JH, Gearin G, Laffel L, Krolewski AS. Effect of duration of type 1 diabetes on the prevalence of stages of diabetic nephropathy defined by urinary albumin/creatinine ratio. *J Am Soc Nephrol*. 1996;7(6):930-7. [PubMed: [8793803](#)].
22. Bursell SE, Clermont AC, Aiello LP, Aiello LM, Schlossman DK, Feener EP, et al. High-dose vitamin E supplementation normalizes retinal blood flow and creatinine clearance in patients with type 1 diabetes. *Diabetes Care*. 1999;22(8):1245-51. [PubMed: [10480765](#)].
23. Balakumar P, Chakkarwar VA, Singh M. Ameliorative effect of combination of benfotiamine and fenofibrate in diabetes-induced vascular endothelial dysfunction and nephropathy in the rat. *Mol Cell Biochem*. 2009;320(1-2):149-62. doi: [10.1007/s11010-008-9917-z](#). [PubMed: [18830571](#)].
24. Chen L, Zhang J, Zhang Y, Wang Y, Wang B. Improvement of inflammatory responses associated with NF-kappa B pathway in kidneys from diabetic rats. *Inflamm Res*. 2008;57(5):199-204. doi: [10.1007/s00011-006-6190-z](#). [PubMed: [18465086](#)].
25. Rosenson RS, Wolff DA, Huskin AL, Helenowski IB, Rademaker AW. Fenofibrate therapy ameliorates fasting and postprandial lipoproteinemia, oxidative stress, and the inflammatory response in subjects with hypertriglyceridemia and the metabolic syndrome. *Diabetes Care*. 2007;30(8):1945-51. doi: [10.2337/dc07-0015](#). [PubMed: [17483155](#)].
26. Montagnani M, Chen H, Barr VA, Quon MJ. Insulin-stimulated activation of eNOS is independent of Ca²⁺ but requires phosphorylation by Akt at Ser(1179). *J Biol Chem*. 2001;276(32):30392-8. doi: [10.1074/jbc.M103702200](#). [PubMed: [11402048](#)].
27. Goya K, Sumitani S, Xu X, Kitamura T, Yamamoto H, Kurebayashi S, et al. Peroxisome proliferator-activated receptor alpha agonists

increase nitric oxide synthase expression in vascular endothelial cells. *Arterioscler Thromb Vasc Biol.* 2004;**24**(4):658-63. doi:

[10.1161/01.ATV.0000118682.58708.78](https://doi.org/10.1161/01.ATV.0000118682.58708.78). [PubMed: [14751809](https://pubmed.ncbi.nlm.nih.gov/14751809/)].