

Thoracic Insufficiency Syndrome: An Overview

Norman Ramirez,^{1,2,*} Sigfredo Villarín,² Robert Ritchie,³ and Kenira J. Thompson⁴

¹Mayaguez Medical Center, Mayaguez, Hospital de la Concepcion, San German, Puerto Rico

²School of Medicine, Ponce Health Sciences University, Ponce, Puerto Rico

³Ponce Research Institute, Ponce, Puerto Rico

⁴Department of Physiology, Neuroscience Division, Ponce Health Sciences University, Ponce Research Institute, Ponce, Puerto Rico

*Corresponding author: Norman Ramirez, Mayaguez Medical Center, Mayaguez, Hospital de la Concepcion, San German, P. O. Box: 6847, Mayaguez, Puerto Rico. Tel: +1-7872642066, E-mail: normanpipe@aol.com

Received 2015 September 14; Accepted 2015 October 2

Abstract

Context: Thoracic insufficiency syndrome is a condition in which the thorax is unable to support either normal respiration or lung growth. This condition is a progressive one, and it can further develop into restrictive lung disease.

Evidence Acquisition: Currently, there is no simple laboratory test that can be used to identify thoracic insufficiency syndrome; it can, however, be identified based on a given patient's history of respiratory symptoms, the findings of a physical examination, radiographs, computed tomography scans, pulmonary function studies and other laboratory tests of respiratory function. As is the case with other medical conditions, this syndrome should be monitored with clinical and radiological evaluations. However, if a patient undergoes obvious deterioration (as determined by clinical, radiological, and laboratory assessments), surgical intervention is advised. The most commonly proposed surgical intervention involves the use of a device known as the vertical expandable prosthetic titanium rib (VEPTR).

Results: A direct enlargement of the thorax that will thus provide sufficient space for lung growth; the correction of both the three-dimensional thoracic deformity and the progressive scoliosis. Recent findings have revealed that VEPTR instrumentation can result in a modest correction of the Cobb angle, with a decrease in the percentage of the predicted forced vital capacity value and accompanying chest-wall stiffness and decreased respiratory system compliance.

Conclusions: Getting a complete knowledge of the condition and evaluating different treatment modalities to treat Thoracic Insufficiency Syndrome.

Keywords: Jeune Syndrome, Myelomeningocele, Surgical Complications, Jarcho Levin, Spondylocostal Dysplasia, Spondylothoracic Dysplasia, VEPTR, Thoracic Insufficiency Syndrome

1. Context

Structurally, the thorax consists of the spine, the rib cage, the sternum and the diaphragm (1, 2). The thorax, a respiratory pump, achieves lung expansion primarily through the contraction of the diaphragm, with the rib cage providing passive support around the lungs (1, 2). This expansion is aided by the intercostal muscle contraction, which is responsible for the anterior and lateral expansion of the rib cage (1, 2).

Two characteristics of a normal thorax are: to have a normal and stable volume, and to have the ability to vary that volume as necessary. The height of the thorax is defined by the height of the thoracic spine; the width and depth are determined by the configuration of the rib cage; adequate thoracic height, width, and depth are all required in order to ensure that volume remains normal (1, 2). A combination of the diaphragm inserting at the T12 level and the active motion of the ribs regulates volume, and this motion is itself dependent on the separate ribs, the intercostal muscles, and the symmetrical nature of the thorax (1, 2). Any deformity of the thoracic spine

or the rib cage will directly affect the respiratory mechanism because lung development is dependent on the growth of the thoracic spine (1, 2).

The components of the rib-vertebral-sternal complex must be in perfect sync (3). The thoracic cage and lungs need to develop properly, and enlarge uniformly during childhood and adolescence. Their growth must be linked to the increase of the thoracic spine height, the symmetrical extension of the rib cage, and the correct orientation of the ribs (2).

The thoracic spine provides the vertical component of thoracic volume (2). The longitudinal growth of the thoracic spine in normal children is about 1.3 cm/year from birth to 5 years of age, 0.7 cm/year from the ages of 5 to 10 years, and 1.1 cm/year during puberty (2, 3). Thoracic spine height is age dependent with the averages being 12 cm at birth, 18 cm at five year of age, and 27 cm at skeletal maturity (3). More than 18 cm of thoracic spine height at skeletal maturity is necessary to avoid respiratory problems (3-5). At birth, thoracic depth and width are similar, with

the ratio of thoracic depth to thoracic width approaching 1 (3). As a child's skeleton reaches maturity, that ratio falls as width increases more rapidly than depth does. Essentially, when the individual reaches skeletal maturity, the general shape of the thoracic cage changes from being ovoid at birth to being elliptical (3, 6).

Overall thoracic volume increases with the changes in the length and shape of the rib (these changes create a greater cross-section of the thorax) coupled with the increase in thoracic height, the gradual separation of the ribs, and costo-sternal growth. In newborns, the volume of the thoracic cage is about 6% of the size that it will attain maturity; by age 5, volume increases to 30% of its eventual total and the trunk attains as much as 66% of its final height; and by age 10, volume reaches about 50% of its eventual total (2, 3). From age 10 to skeletal maturity, before ceasing to grow, a child's thoracic cage doubles its volume. The average depth of the thorax of a boy who has attained his full growth is 21 cm and the average width is 28 cm; for a girl, that average is 17.7 cm in depth and 24.7 cm in width (3).

In terms of lung growth, newborns have the same number of conducting airways as adults do. From birth to 4 years of age, the number of alveoli increases by a factor of 10, and at 8 to 9 years of age, the development of the bronchial tree is supposed to be complete. During the entire process, increases in the number and complexity of the alveoli, greater capillary development, and the process of septation all contribute toward an eventual 10-fold increase to the alveolar and capillary surface areas (2, 3).

Any spinal deformity that might develop during this process will affect the growth of the spine, subsequently altering the eventual size and shape of the thoracic cage (1, 2). As a consequence, lung development and thoracic function are negatively affected; children who suffer from this kind of alteration of the thorax almost invariably develop thoracic insufficiency syndrome (TIS). TIS is defined as "the inability of the thorax to support normal respiration or lung growth" (1, 2, 4, 5, 7-10).

TIS can be divided into two types. The first, primary TIS, is used to refer to disorders of the thoracic and spinal structures that directly impair lung function. Primary TIS can be seen in volume-depletion deformities such as Jarcho-Levin, Jeune syndrome, congenital scoliosis and in patients being treated with early spine arthrodesis (2, 11).

When the torso is collapsed onto the pelvis and there is an increase in reactive abdominal pressure limiting downward diaphragmatic function, this condition is defined as secondary TIS. This type of syndrome is most commonly seen in myelomeningocele patients with lumbar kyphosis (2, 4).

In their respective studies, Ramirez et al. (11) and Karol et al. (5) used natural history models of spondylothoracic dysplasia in the same patients as well as in patients requiring early spinal fusion in order to describe the natural history of primary TIS. The main purpose for their having done so was so that a direct assessment of the effect of

primary TIS could be made (5, 11). It should be noted that nothing has so far been published about the natural history of secondary TIS in patients with spina bifida.

2. Evidence Acquisition

2.1. Diagnosis

TIS as a progressive condition can further develop into restrictive lung disease (2). There is currently no simple laboratory test that can be used to identify TIS. A diagnosis of TIS must be made using a given patient's history of respiratory symptoms together with the findings of a physical examination, radiographs, computed tomography scans, and pulmonary function studies and any other laboratory tests of respiratory function that might be deemed necessary (1, 2, 10).

Fatigability, the failure to gain weight, several episodes of pneumonia, the need for oxygen support, and an increasing frequency of hospitalization due to respiratory problems over the previous year are some of the events and circumstances that might be part of a given patient's history. Oxygen dependence is not characterized as a main criterion for the diagnosis of TIS, because while deficiencies in thoracic performance can diminish respiratory efficiency, compensatory mechanisms can obfuscate the true nature of the clinical situation (1, 2, 10).

In terms of the physical examination, the presence of a deformity of the thorax is clinically determined by chest palpation and inspection; the affected region is usually shortened both longitudinally and transversely. There may be limited mobility of the chest wall on the affected side (as measured by the thumb excursion test), but without clubbing of the fingers or perioral cyanosis (1, 2, 10).

Several parameters such as the Cobb angle, which will reflect a decrease of the height of the spine could be evaluated using a posterior-anterior radiograph. Vertebral rotation, alteration of the sagittal contour of the spine, a decrease of thoracic spine height, and space available for the lungs, are other parameters that can be evaluated using an x-ray. "Space available for the lungs" refers to the ratio of the height of the concave side compared with that of the convex side expressed as percentage (1).

The transverse section of a computed tomography scan may contribute to the understanding of the three-dimensional deformity of the thorax. Increased vertebral and thoracic rotation, reduced sagittal depth of the thorax, and a decrease of the hemithorax volume are other parameters that can be assessed using this radiological instrumentation (1, 2).

Another test that is used to measure progressive restrictive lung disease in TIS patients is the standard pulmonary function test. Decreases in pulmonary function measures could indicate the presence of lung fibrosis or reactive airway disease or point to a reduction in the volume and function of the thorax. It should be mentioned that laboratory measurements of serum electrolytes and

arterial or capillary blood gases might be normal (1).

Campbell et al. developed a system for classifying volume depletion deformities using radiograph and computed tomography studies of the thorax (2). Patients with scoliosis and who have missing ribs are said to have a type I volume depletion deformity; this is a kind of physiologic asymmetric unilateral thoracic hypoplasia in which the underlying anatomic defect is a prolapse of a lung, resulting in severe volume loss. Examples of this include the VATER association as well as absent ribs and congenital scoliosis.

Clinically, VATER association is an acronym that refers to a constellation of statistically non-random and co-occurring congenital malformations, those malformations consisting of vertebral defects, anal atresia, tracheoesophageal fistula (TEF) with esophageal atresia, and radial and renal dysplasia. Quan and Smith first named the association in 1973. Though no firm consensus regarding specific diagnostic criteria has yet been reached, most clinicians and researchers look for at least three of the components to make a diagnosis, without including clinical or laboratory-based evidence of any overlapping conditions that might be present; others instead search for the characteristics of the different components, especially a tracheoesophageal fistula or an anorectal malformation (12-14).

Fused ribs and scoliosis are the conditions that fall under the type II category of volume depletion deformities. This is a kind of unilateral thoracic hypoplasia that is caused by constriction of the lung volume due to fused ribs. The rib cage on the concave side is described as the constricted hemithorax, whereas the chest on the contralateral side is described as the convex hemithorax. Examples of this type II of volume-depletion deformity include VATER association, spondylocostal dysplasia (Jarcho-Levin), thoracogenic scoliosis from a prior thoracotomy, and those patients treated with an early spine fusion (2, 5).

Type IIIa volume-depletion deformities consist of global thoracic hypoplasia with bilateral longitudinal constriction of the lung from loss of the thoracic height. An example of this is spondylothoracic dysplasia (Jarcho-Levin) (2).

In 1938 Jarcho and Levin described a condition composed of extensive vertebral malformation that led to the early deaths of two siblings. Since then several types of short-trunk dwarfism, characterized by multiple segmentation defects of the vertebral bodies and ribs, have been described, including spondylocostal dysplasia, spondylocostal dysostosis, spondylothoracic dysplasia, costovertebral dysplasia, and occipito-facial-cervicothoracic-abdomino digital dysplasia. In 1974, Perez-Comas and Garcia Castro grouped all the patients with spinal segmentation, formation defects, and rib fusion anomalies under the eponymic name "Jarcho-Levin syndrome" (11, 15-17).

Later, in 1978, Solomon et al. divided Jarcho-Levin pa-

tients into two groups: spondylothoracic dysplasia and spondylocostal dysplasia (18). The term "spondylocostal dysplasia" was suggested to refer to patients with associated unilateral intrinsic changes of the ribs, such as broadening, bifurcation, and fusion (without the fan-like configuration of the thorax that is indicative of spondylothoracic dysplasia) (11, 15, 16, 18). The genetic etiology of the syndrome has been linked to chromosome 19q13.1-19q13.3 and mutations in the DLL3 gene (19). While early deaths resulting from respiratory causes have been reported in association with spondylocostal dysplasia, it is reported that patients with spondylocostal dysplasia had a better survival rate and overall prognosis than those with spondylothoracic dysplasia (11).

The diagnosis of spondylothoracic dysplasia was reserved for patients with an apparent autosomal recessive pattern of transmission and a fan-like configuration of the ribs (crab-like chest), caused by the fusion of all ribs at the costovertebral junctions, without intrinsic costal anomalies (11, 15, 16). Cornier et al. denoted a separate molecular etiology for spondylothoracic patients (mutation in the MESP2 gene) (20). Forty-nine percent of the patients described in the medical literature as suffering from spondylothoracic dysplasia were of Puerto Rican ancestry. The vast majority of the patients described had poor prognoses because of the respiratory complications (e.g., pneumonia, congestive heart failure, pulmonary hypertension) associated with the condition. Though described throughout the literature as a lethal disorder, the condition has been demonstrated (in a study by Cornier et al.) to be in fact not imminently lethal, having, according to the aforementioned study, a mortality rate of 44%, which is high but not as high as the rate has been described (15).

Type IIIb patients are those patients with a transverse constriction of the thorax. The main pathology is also global thoracic hypoplasia, but in these patients it is secondary to the lateral constriction of the lung from rib deformity, such as occurs, for example, with Jeune syndrome (2).

Asphyxiating thoracic dysplasia, also called, Jeune syndrome, is a rare form of skeletal dysplasia linked to an autosomal recessive gene; it is characterized by a small, narrow thorax and foreshortened limbs. Respiratory arrest is a frequent cause of death in neonates with the syndrome. Jeune et al. first described the condition in 1955. Estimates indicate that approximately 40 babies with Jeune syndrome are born every year in the United States over 600 are born worldwide. A locus on chromosome 15q13 has been identified. Most patients (60% - 80%) are severely affected and die in the perinatal period from asphyxia caused by the small thorax and hypoplastic lungs that comprise the disorder (8, 21-24).

A diagnosis of Jeune syndrome is established at using clinical and radiographic findings, and as one can gather from the above, it is clinically characterized as a small, narrow chest and foreshortened limbs. A congenital ab-

normality sometimes (20%) associated with the syndrome is postaxial polydactyly of the hands or feet or both. Radiographic findings typically feature a bell-shaped and unusually narrow thorax consisting of short, horizontally oriented ribs with abnormal costochondral junctions; short iliac bones together with trident-shaped acetabula; raised (“handlebar”) clavicles; extremities whose long bones are unusually short and wide; and hands and feet with incompletely developed fingers and toes, respectively, that have cone-shaped epiphyses (21, 24).

This specific description is intended to enable the clinician to visualize the mechanical defects of the thoracic spine, chest, and lungs so that he or she might then be able to provide an appropriate treatment algorithm.

2.2. Treatment

As is the case with any medical condition, stable TIS should be regularly monitored, with periodic evaluations (clinical and radiological) being made. However, in case of obvious deterioration (as determined by clinical, radiological, and laboratory findings of TIS progression), a surgical intervention is advised. Excepting those cases requiring immediate action, interventions for correcting such disorders will in all likelihood (depending on the specific nature of the spine’s and lungs’ growth) need to take place before the patient reaches 8 years of age. The proposed surgical intervention for TIS has been the implantation of a VEPTR (1, 2, 4, 10, 25, 26).

The VEPTR implant is a device constructed of titanium; it is roughly rectangular in cross-section, with two standard curvatures, both conforming to the shape of the thoracic cage in which it is being implanted. The device is placed along the chest wall (vertically) with the two ends being attached to healthy bone (a rib, a section of the spine, or the pelvis) above and below the side of abnormality. In addition to separating the ribs and expanding the chest wall, the device acts as a kind of protective internal splint over the area of the deformity. Further, the implanted VEPTR device can indirectly apply distraction in order to control or improve the associated scoliosis (4).

Requiring thoracic surgery, the goal of the device implantation is to enlarge and stabilize the malformed chest and the correction of the existing scoliosis, by the time he or she reaches skeletal maturity (25, 27). Usually the patient is placed in a lateral decubitus position, with the thorax and the exposed arm prepped and draped free. The exposure is designed to facilitate the procedure (opening wedge thoracostomy) and allow access to the entire chest wall for device placement and expansion. It is recommended that dissection be extraperiosteal, which preserves vascular supply to the ribs and leaves the intercostal vessels and muscles as intact as possible. The upper cradle of the device should not involve the first rib, and, in order to avoid brachial plexopathy, it should not pass in front of the middle scalene muscle. The lower

cradle should not be affixed to any unstable or “floating” ribs. After having been implanted, the device is periodically lengthened every 6 months as the thoracic spine grows (2, 4).

Following the Campbell volume-depletion classification, several VEPTR surgical constructs have been proposed to correct TIS. In type I patient, such as those with a VATER syndrome, the recommended treatment consists of an open thoracotomy, with the stabilization of the flailed chest and the lengthening of the collapsed hemithorax being accomplished with multiple rib-to-rib VEPTRs. In cases in which the proximal ribs are completely absent, the VEPTR attachment can be carried out using a clavicle augmentation (4, 10).

In type II patients with fused ribs and scoliosis (indicating spondylocostal dysplasia), the fused ribs are divided at the center of the bony mass via one or two transverse rib osteotomies, after which the constricted hemithorax is lengthened by dissecting the proximal from the distal ribs or spine attachment (4, 10). Currently, there are only two reports addressing VEPTR treatment in patients with spondylocostal dysplasia. Ramirez et al. (28) and Karlin et al. (29) reported achieving control of the spinal deformity, with adequate thoracic growth and improvement of the respiratory status following the procedure (4) (Figures 1 and 2).

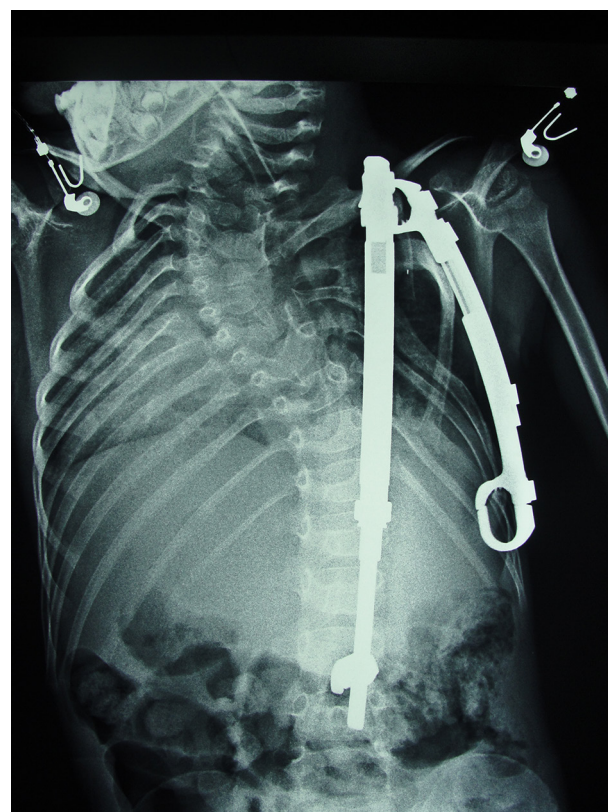


Figure 1. AP Radiograph of a 7-Year-Old Spondylocostal Boy Patient With a Rib to Rib and Rib to Spine VEPTR

In patients with type IIIa deformities and who have symmetrically shortened chests because of bilateral rib fusion and shortened thoracic spine, such as what is seen in spondylothoracic dysplasia, a modified opening wedge thoracotomy can be used to lengthen the shortened rib cage. Only one study addressed the treatment of spondylothoracic dysplasia using a VEPTR. Karlin et al. reported an improvement to thoracic symmetry and a reduction of deformity coupled with an increase of clinical respiratory function (29). However, both Cornier et al. (15) and Ramirez et al. (11) recommended that no surgical intervention be undertaken, because their spondylothoracic dysplasia study group patients were well in clinical terms and had adequate quality of life in spite of poor vital capacity.

For patient with type IIIb hypoplastic thorax that is caused by narrowing, such as Jeune syndrome, movement of the chest wall is restored by performing anterior and posterior osteotomies of ribs 3 through 8. Doing so creates a large flailed chest-wall segment that, once it has been brought out laterally, is attached to a special, curved rib-to-rib VEPTR (with a 7 cm radius) that acts as a support arch for the expanded chest. The technique is also useful for unilateral types of transverse volume-depletion deformities that are often seen in VATER syndrome (4).

In a patient with secondary thoracic insufficiency syndrome, such as a non-ambulatory myelomeningocele patient, a bilateral rib-to-pelvis construct is recommended in order to get support from the pelvis, to correct the spinal deformity, and to minimize the diaphragm's extrusion into the chest cavity (4, 30) (Figures 3 - 5).

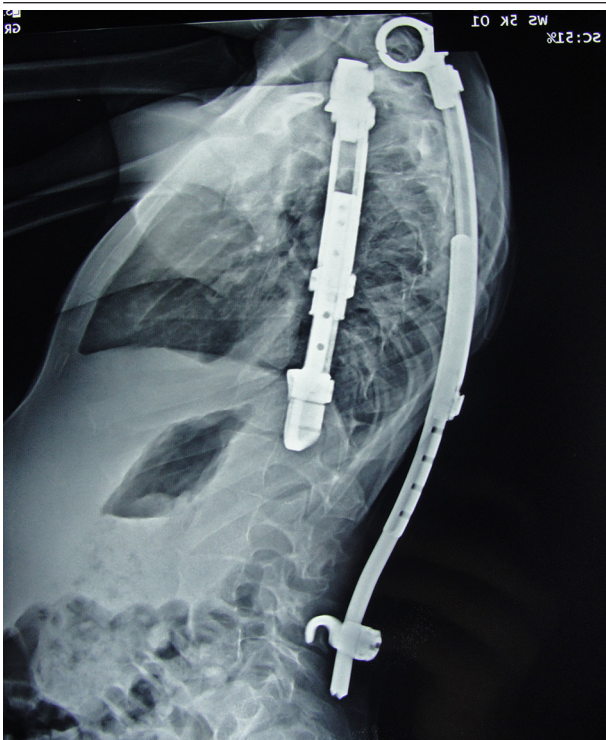


Figure 2. Lateral Radiograph of a 7-Year-Old Spondylocostal Dysplasia Boy Patient With a Rib to Rib and Rib to Spine VEPTR

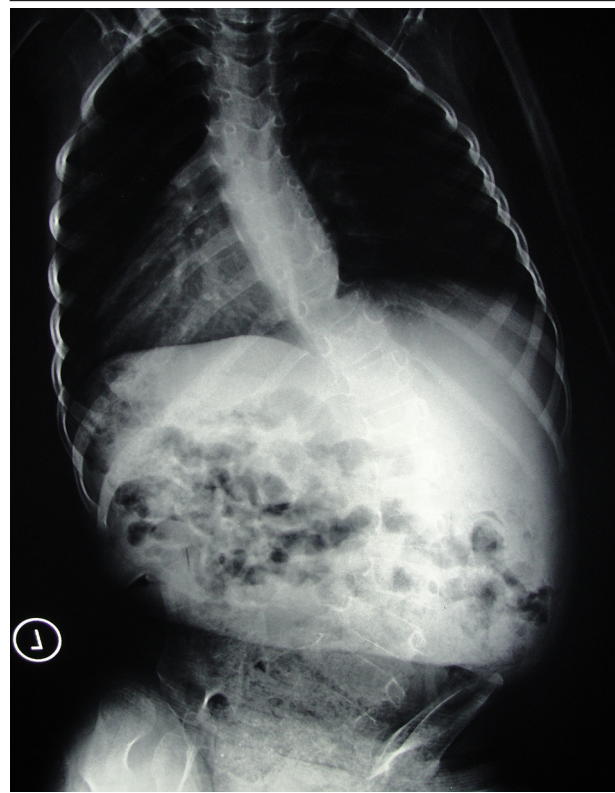

Figure 3. Ap Radiograph of a 8 Year Old Patient With a Neuromuscular Scoliosis Due to None Ambulatory Myelomeningocele

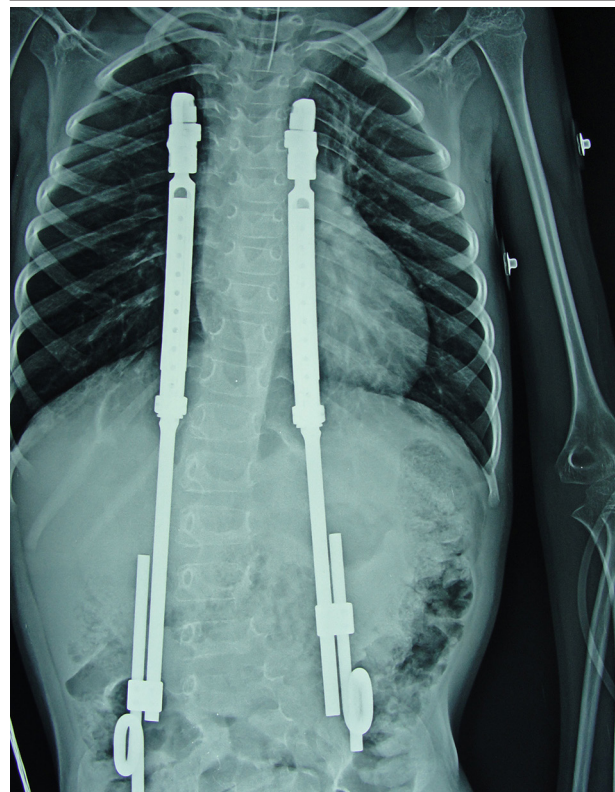


Figure 4. AP Radiograph 8-Year-Old Boy Patient With None Ambulatory Myelomeningocele Status Post Bilateral Rib to Pelvis VEPTR

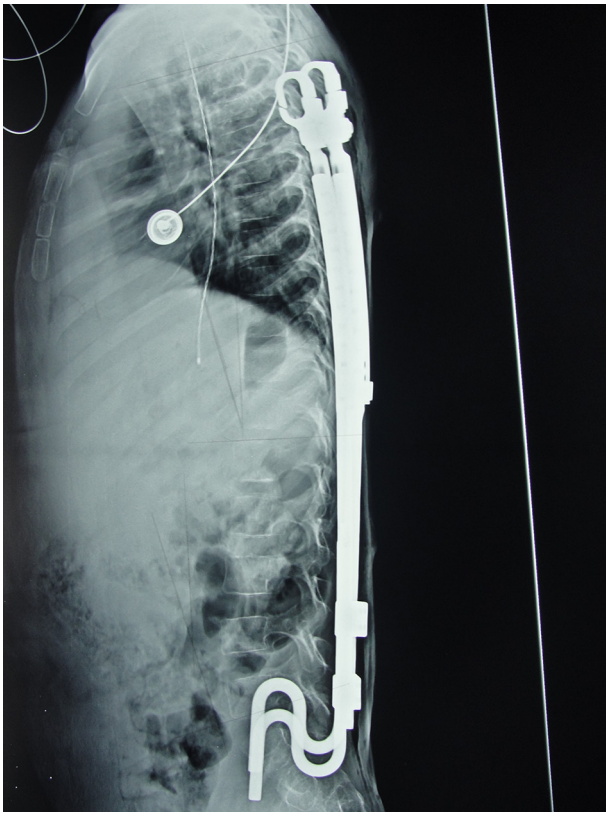


Figure 5. Lateral Radiograph 8-Year-Old Boy Patient With None Ambulatory Myelomeningocele Status Post Bilateral Rib to Pelvis VEPTR

3. Results

In theory, the main benefits of implanting a VEPTR device should be that the thorax will be enlarged, thereby providing a better space for lung growth; the three-dimensional thoracic deformity will be decreased; and the scoliosis condition will be corrected (2, 4, 7-10, 25-32). A less direct benefit that has been seen is that TIS patients presenting compromised nutritional status before surgery have demonstrated weight gains after having undergone the implantation of the VEPTR device (33). However, the most recent results revealed that VEPTR implantation produced only modest corrections of the Cobb angle, with a tendency toward increasing kyphosis during the treatment period (25). Regarding the effect of VEPTR treatment on the pulmonary function of TIS patients, pulmonary function studies showed a decrease in the percentage of the predicted forced vital capacity, with chest-wall stiffness and decreased respiratory system compliance (7, 25, 31, 34). Thus, the expected respiratory benefits of the surgery have not been clearly demonstrated. The findings of these studies raise questions about the utility of VEPTR implantation in treating TIS (25, 31, 34).

As is the case with any surgical procedure, VEPTR device implantation can have complications. The complication rate ranges from 10 to 40% (4, 7, 10, 26, 27). The majority

of the complications are treatable and do not require that the treatment be suspended (35). The most common complication is the asymptomatic proximal migration of the device through the ribs of the proximal attachment, followed by rib fractures that are caused by the increase in pressure resulting from the lengthening of the device (7, 10). Distally, in the rib-to-pelvis construct (the so-called Eiffel Tower construct), the most common complication is the sliding of the distal attachment out of the iliac crest, itself secondary to several technical factors (36).

Brachial plexus injuries and/or vascular complications have been reported in 10% of the cases. Postoperative upper-extremity dysfunction could be attributed to an iatrogenic thoracic outlet syndrome caused by the compression of the brachial plexus within the costoclavicular space after expansion thoracoplasty. The rates of neurologic injury during surgical procedures (principally in the initial implantation and during device exchange) justify the use of intraoperative monitoring during VEPTR surgery (37).

Each new incision is a new opportunity for wound infection or skin slough. The infection rate ranges from 1.9 to 30% (2, 26, 27, 38, 39). 40% of myelomeningoceles patients report at least one surgical wound complication (2, 30).

4. Conclusions

Much more remains to be learned about TIS and how different diagnostic tools and treatment could help patients having this syndrome have a better quality of life. Several studies reported that children with TIS frequently experience considerable limitations in their emotional lives due to their health problems (40, 41).

The natural history, diagnosis, prevention, and treatment of secondary TIS in spina bifida patients require additional attention from clinicians.

It is important to come to a better understanding of how VEPTRs can be used as part of an overall treatment strategy to reverse respiratory insufficiency associated with three-dimensional thoracic deformity. A prospective surgical trial comparing VEPTR implantation to other techniques is essential, and with it, an assessment of this technique's capacity for correcting thoracic deformity and improving pulmonary outcomes needs to be made.

Footnote

Authors' Contribution: Norman Ramirez: study concept and design, acquisition of data, analysis and interpretation of data, drafting of the manuscript, critical revision of the manuscript for important intellectual content, administrative, technical, and material support and study supervision. Sigfredo Villarín: acquisition of data, drafting of the manuscript, critical revision of the manuscript for important intellectual content. Robert Ritchie: acquisition of data, drafting of the manuscript, critical revision of the manuscript for important intellectual content, administrative, technical, and material support. Kenira J.

Thompson: analysis and interpretation of data, drafting of the manuscript, critical revision of the manuscript for important intellectual content, administrative, technical, and material support, study supervision.

References

- Campbell RM, Smith MD, Mayes TC, Mangos JA, Willey-Courand DB, Kose N, et al. The characteristics of thoracic insufficiency syndrome associated with fused ribs and congenital scoliosis. *J Bone Joint Surg Am.* 2003;**85-A**(3):399–408. [PubMed: 12637423]
- Campbell RM, Smith MD. Thoracic insufficiency syndrome and exotic scoliosis. *J Bone Joint Surg Am.* 2007;**89 Suppl 1**:108–22. doi: 10.2106/JBJS.F.00270. [PubMed: 17272428]
- Canavese F, Dimeglio A. Normal and abnormal spine and thoracic cage development. *World J Orthop.* 2013;**4**(4):167–74. doi: 10.5312/wjo.v4.i4.167. [PubMed: 24147251]
- Campbell RM. VEPTR: past experience and the future of VEPTR principles. *Eur Spine J.* 2013;**22 Suppl 2**:S106–17. doi: 10.1007/s00586-013-2671-2. [PubMed: 23354777]
- Karol LA, Johnston C, Mladenov K, Schochet P, Walters P, Browne RH. Pulmonary function following early thoracic fusion in non-neuromuscular scoliosis. *J Bone Joint Surg Am.* 2008;**90**(6):1272–81. doi: 10.2106/JBJS.G.00184. [PubMed: 18519321]
- Dimeglio A, Canavese F. The growing spine: how spinal deformities influence normal spine and thoracic cage growth. *Eur Spine J.* 2012;**21**(1):64–70. doi: 10.1007/s00586-011-1983-3. [PubMed: 21874626]
- Waldhausen JH, Redding GJ, Song KM. Vertical expandable prosthetic titanium rib for thoracic insufficiency syndrome: a new method to treat an old problem. *J Pediatr Surg.* 2007;**42**(1):76–80. doi: 10.1016/j.jpedsurg.2006.09.059. [PubMed: 17208544]
- Betz RR, Mulcahey MJ, Ramirez N, Flynn JM, Smith JT, St Hilaire T, et al. Mortality and life-threatening events after vertical expandable prosthetic titanium rib surgery in children with hypoplastic chest wall deformity. *J Pediatr Orthop.* 2008;**28**(8):850–3. doi: 10.1097/BPO.0b013e31818e19a4. [PubMed: 19034177]
- Mayer OH. Management of thoracic insufficiency syndrome. *Curr Opin Pediatr.* 2009;**21**(3):333–43. doi: 10.1097/MOP.0b013e328329a500. [PubMed: 19454896]
- Campbell RM, Smith MD, Mayes TC, Mangos JA, Willey-Courand DB, Kose N, et al. The effect of opening wedge thoracotomy on thoracic insufficiency syndrome associated with fused ribs and congenital scoliosis. *J Bone Joint Surg Am.* 2004;**86-A**(8):1659–74. [PubMed: 15292413]
- Ramirez N, Cornier AS, Campbell RM, Carlo S, Arroyo S, Romeu J. Natural history of thoracic insufficiency syndrome: a spondylothoracic dysplasia perspective. *J Bone Joint Surg Am.* 2007;**89**(12):2663–75. doi: 10.2106/JBJS.F.01085. [PubMed: 18056499]
- Solomon BD. VACTERL/VATER Association. *Orphanet J Rare Dis.* 2011;**6**:56. doi: 10.1186/1750-1172-6-56. [PubMed: 21846383]
- Mori M, Matsubara K, Abe E, Matsubara Y, Katayama T, Fujioka T, et al. Prenatal diagnosis of persistent cloaca associated with VATER (vertebral defects, anal atresia, tracheo-esophageal fistula, and renal dysplasia). *Tohoku J Exp Med.* 2007;**213**(4):291–5. [PubMed: 18075232]
- Bartels E, Jenetzky E, Solomon BD, Ludwig M, Schmiedeke E, Grasshoff-Derr S, et al. Inheritance of the VATER/VACTERL association. *Pediatr Surg Int.* 2012;**28**(7):681–5. doi: 10.1007/s00383-012-3100-z. [PubMed: 22581124]
- Cornier AS, Ramirez N, Arroyo S, Acevedo J, Garcia L, Carlo S, et al. Phenotype characterization and natural history of spondylothoracic dysplasia syndrome: a series of 27 new cases. *Am J Med Genet A.* 2004;**128A**(2):120–6. doi: 10.1002/ajmg.a.30011. [PubMed: 15214000]
- Cornier AS, Ramirez N, Carlo S, Reiss A. Controversies surrounding Jarcho-Levin syndrome. *Curr Opin Pediatr.* 2003;**15**(6):614–20. [PubMed: 14631208]
- Perez-Comas A, Garcia-Castro JM. Occipito-facial-cervico-thoracic-abdomino-digital dysplasia; Jarcho-Levin syndrome of vertebral anomalies. Report of six cases and review of the literature. *J Pediatr.* 1974;**85**(3):388–91. [PubMed: 4372555]
- Solomon L, Jimenez RB, Reiner L. Spondylothoracic dysostosis: report of two cases and review of the literature. *Arch Pathol Lab Med.* 1978;**102**(4):201–5. [PubMed: 350188]
- Turnpenny PD, Whittock N, Duncan J, Dunwoodie S, Kusumi K, Ellard S. Novel mutations in DLL3, a somitogenesis gene encoding a ligand for the Notch signalling pathway, cause a consistent pattern of abnormal vertebral segmentation in spondylocostal dysostosis. *J Med Genet.* 2003;**40**(5):333–9. [PubMed: 12746394]
- Cornier AS, Staehling-Hampton K, Delventhal KM, Saga Y, Caubet JF, Sasaki N, et al. Mutations in the MESP2 gene cause spondylothoracic dysostosis/Jarcho-Levin syndrome. *Am J Hum Genet.* 2008;**82**(6):1334–41. doi: 10.1016/j.ajhg.2008.04.014. [PubMed: 18485326]
- de Vries J, Yntema JL, van Die CE, Crama N, Cornelissen EA, Hamel BC. Jeune syndrome: description of 13 cases and a proposal for follow-up protocol. *Eur J Pediatr.* 2010;**169**(1):77–88. doi: 10.1007/s00431-009-0991-3. [PubMed: 19430947]
- Davis T. Chest wall surgery for asphyxiating thoracic surgery. *Pediatr Pulmonol Suppl.* 2004;**26**:136–7. [PubMed: 15029629]
- Morgan NV, Bacchelli C, Gissen P, Morton J, Ferrero GB, Silengo M, et al. A locus for asphyxiating thoracic dystrophy, ATD, maps to chromosome 15q13. *J Med Genet.* 2003;**40**(6):431–5. [PubMed: 12807964]
- Oberklaid F, Danks DM, Mayne V, Campbell P. Asphyxiating thoracic dysplasia. Clinical, radiological, and pathological information on 10 patients. *Arch Dis Child.* 1977;**52**(10):758–65. [PubMed: 931421]
- Dede O, Motoyama EK, Yang CI, Mutich RL, Walczak SA, Bowles AJ, et al. Pulmonary and Radiographic Outcomes of VEPTR (Vertical Expandable Prosthetic Titanium Rib) Treatment in Early-Onset Scoliosis. *J Bone Joint Surg Am.* 2014;**96**(15):3295–302. doi: 10.2106/JBJS.M.01218. [PubMed: 25100777]
- Hell AK, Campbell RM, Hefti F. The vertical expandable prosthetic titanium rib implant for the treatment of thoracic insufficiency syndrome associated with congenital and neuromuscular scoliosis in young children. *J Pediatr Orthop B.* 2005;**14**(4):287–93. [PubMed: 15931035]
- Ramirez N, Flynn JM, Serrano JA, Carlo S, Cornier AS. The Vertical Expandable Prosthetic Titanium Rib in the treatment of spinal deformity due to progressive early onset scoliosis. *J Pediatr Orthop B.* 2009;**18**(4):197–203. doi: 10.1097/BPB.0b013e32832b1f5e0. [PubMed: 19390461]
- Ramirez N, Flynn JM, Emans JB, Betz R, Smith JT, Price N, et al. Vertical expandable prosthetic titanium rib as treatment of thoracic insufficiency syndrome in spondylocostal dysplasia. *J Pediatr Orthop.* 2010;**30**(6):521–6. doi: 10.1097/BPO.0b013e3181e78e6c. [PubMed: 20733413]
- Karlin JG, Roth MK, Patil V, Cordell D, Trevino H, Simmons J, et al. Management of thoracic insufficiency syndrome in patients with Jarcho-Levin syndrome using VEPTRs (vertical expandable prosthetic titanium ribs). *J Bone Joint Surg Am.* 2014;**96**(21):e181. doi: 10.2106/JBJS.M.00185. [PubMed: 25378514]
- Flynn JM, Ramirez N, Emans JB, Smith JT, Mulcahey MJ, Betz RR. Is the vertebral expandable prosthetic titanium rib a surgical alternative in patients with spina bifida? *Clin Orthop Relat Res.* 2011;**469**(5):1291–6. doi: 10.1007/s11999-010-1620-1. [PubMed: 20941646]
- Mayer OH, Redding G. Early changes in pulmonary function after vertical expandable prosthetic titanium rib insertion in children with thoracic insufficiency syndrome. *J Pediatr Orthop.* 2009;**29**(1):35–8. doi: 10.1097/BPO.0b013e3181929c8b. [PubMed: 19098643]
- Campbell RM, Hell-Vocke AK. Growth of the thoracic spine in congenital scoliosis after expansion thoracoplasty. *J Bone Joint Surg Am.* 2003;**85-A**(3):409–20. [PubMed: 12637424]
- Skaggs DL, Sankar WN, Albrektson J, Wren TA, Campbell RM. Weight gain following vertical expandable prosthetic titanium ribs surgery in children with thoracic insufficiency syndrome. *Spine (Phila Pa 1976).* 2009;**34**(23):2530–3. doi: 10.1097/BRS.0b013e3181bd09f5. [PubMed: 19927103]

34. Gadepalli SK, Hirschl RB, Tsai WC, Caird MS, Vanderhave KL, Strouse PJ, et al. Vertical expandable prosthetic titanium rib device insertion: does it improve pulmonary function? *J Pediatr Surg*. 2011;**46**(1):77-80. doi: 10.1016/j.jpedsurg.2010.09.070. [PubMed: 21238644]
35. Sankar WN, Acevedo DC, Skaggs DL. Comparison of complications among growing spinal implants. *Spine (Phila Pa 1976)*. 2010;**35**(23):2091-6. doi: 10.1097/BRS.0b013e3181c6edd7. [PubMed: 20562733]
36. Ramirez N, Flynn JM, Smith JT, Vitale M, Sturm PF, D'Amato C, et al. Use of the S-hook for Pelvic Fixation in Rib-Based Treatment of Early-Onset Scoliosis: A Multicenter Study. *Spine (Phila Pa 1976)*. 2015;**40**(11):816-22. doi: 10.1097/BRS.0000000000000443. [PubMed: 24921843]
37. Skaggs DL, Choi PD, Rice C, Emans J, Song KM, Smith JT, et al. Efficacy of intraoperative neurologic monitoring in surgery involving a vertical expandable prosthetic titanium rib for early-onset spinal deformity. *J Bone Joint Surg Am*. 2009;**91**(7):1657-63. doi: 10.2106/JBJS.G.00202. [PubMed: 19571088]
38. Lucas G, Bollini G, Jouve JL, de Gauzy JS, Accadbled F, Lascombes P, et al. Complications in pediatric spine surgery using the vertical expandable prosthetic titanium rib: the French experience. *Spine (Phila Pa 1976)*. 2013;**38**(25):E1589-99. doi: 10.1097/BRS.0000000000000014. [PubMed: 24048087]
39. Garg S, LaGreca J, St Hilaire T, Gao D, Glotzbecker M, Li Y, et al. Wound complications of vertical expandable prosthetic titanium rib incisions. *Spine (Phila Pa 1976)*. 2014;**39**(13):E777-81. doi: 10.1097/BRS.0000000000000343. [PubMed: 24732832]
40. Vitale MG, Matsumoto H, Roye Jr DP, Gomez JA, Betz RR, Emans JB, et al. Health-related quality of life in children with thoracic insufficiency syndrome. *J Pediatr Orthop*. 2008;**28**(2):239-43. doi: 10.1097/BPO.0b013e31816521bb. [PubMed: 18388722]
41. Flynn JM, Matsumoto H, Torres F, Ramirez N, Vitale MG. Psychological dysfunction in children who require repetitive surgery for early onset scoliosis. *J Pediatr Orthop*. 2012;**32**(6):594-9. doi: 10.1097/BPO.0b013e31826028ea. [PubMed: 22892621]