

Treatment of Hydatid Disease of the Tibia by Using Poly-Methyl Methacrylate (PMMA) Bone Cements, Clinical Results of a Case Series

Mohammad Gharehdaghi¹; Mohammad Hossein Ebrahimzadeh²; Nahid Mojaver³; Hami Ashraf^{3,4}; Hassan Rahimi Shoorin¹; Ali Birjandinejad^{3,*}

¹Orthopedic Research Center, Imam Reza Hospital, School of Medicine, Mashhad University of Medical Sciences, Mashhad, IR Iran

²Orthopedic Research Center, Ghaem Hospital, School of Medicine, Mashhad University of Medical Sciences, Mashhad, IR Iran

³Orthopedic Research Center, Shahid Kamyab Hospital, School of Medicine, Mashhad University of Medical Sciences, Mashhad, IR Iran

⁴Research and Education Department, Razavi Hospital, Mashhad, IR Iran

*Corresponding author: Ali Birjandinejad, Orthopedic Research Center, Shahid Kamyab Hospital, School of Medicine, Mashhad University of Medical Sciences, Mashhad, IR Iran. Tel: +98-5138523300, Fax: +98-5136004360, E-mail: birjandinejada@mums.ac.ir

Received: August 3, 2014; **Revised:** November 29, 2014; **Accepted:** December 6, 2014

Introduction: Bone is an uncommon site of involvement in hydatid disease; with the prevalence of 0.5-2% among bone lesions.

Case Presentation: In this study, we report the treatment of 5 cases of hydatid disease of tibia by curettage of the lesion; wash with Betadine lotion and hypertonic saline and filling the cavity with poly methyl metacrylate (PMMA) bone cement. After operation, we continued treatment with oral mebendazole for 6 months.

Conclusions: With the average 89 months follow-up, no recurrence of the diseases was found in the patients. It seems that using of cement and oral anti-parasitic, after extensive resection of the lesion is a proper treatment of bone hydatid disease.

Keywords: Echinococcosis; Polymethyl Methacrylate; Tibia

1. Introduction

Parasitic hydatid disease is caused by *Echinococcus granulosus* at larval stage and forms the cysts throughout the body. Bone involvement in human includes transmitting from liver and lung filters, spreading through the arterial system and finally reaching the bone. This process rarely happens and consists 0.5 to 2 percents of hydatid diseases in various reports (1-3). Common sites of bone involvement are: long bones (30%), spine (30%), pelvis and hip (20%), ribs and scapula (10%), and phalanges, head and face (10%) (4).

Following bone involvement, cysts form in the medullary cavity and then spread to the cortex, this leads to thinning and destruction of the cortex. Finally they spread to the surrounding soft tissue (1, 5). Since hydatid disease of the bone may remain latent up to 20 years, (6, 7) usually patients present in advanced stages of the disease, with symptoms depending on the affected area as pain, claudication, deformity, pathologic fracture, paralysis, secondary infection, effusion and joint destruction (8, 9). The purpose of this study is the presentation of our findings in bone hydatid cyst treatment by cyst curettage and filling it with Poly-methyl methacrylate (PMMA).

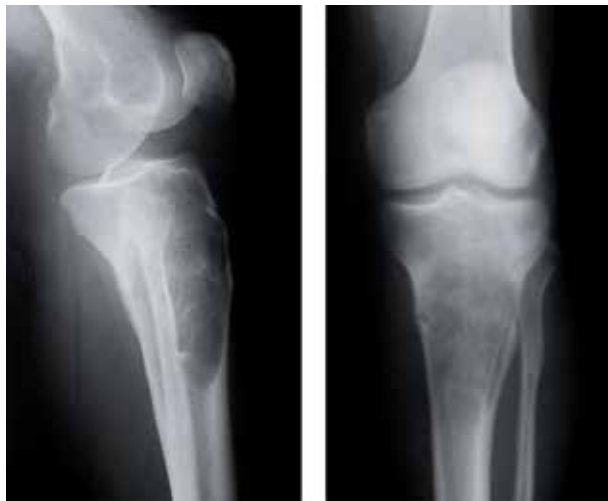2. Case Presentation

Among the patients referred to orthopedic clinic of Mashhad University of Medical Sciences, Mashhad, Iran, with chronic pain, tenderness, limping, knee pain and effusion, and lesions in the X-Ray, in the period of August 1999 to April 2005, we diagnosed five cases of hydatid disease with bone involvement, based on the history, clinical examination and imaging. They were three females and two males with mean age of 51.0 ± 11.1 years old (Table 1). Three patients were from Afghanistan and 2 patients were Iranian.

Diagnostic procedures including plain radiography, Computerized Tomography Scan and MRI were performed in all of the patients; and the diagnosis was confirmed based on the macroscopic and microscopic examination of samples obtained from involved sites. Surgical treatment was accomplished for all the cases. After making an incision in the damaged part and the thinned cortex, a complete curettage of the lesion cavity was done manually and by using a burr, and then it was irrigated by Betadine (Povidone-Iodine) and hypertonic saline. We tried not to contaminate the surrounding soft tissue by draping the area, careful observation and washing out with saline (Figure 1).

Table 1. The Patients' Characteristics

	Age	Gender	Location of Involvement	Mean Follow-up Time	Sign and Symptoms	Duration of Symptoms
Case 1	76	Female	Proximal of Tibia	51 months	Knee Pain, limping and radiographic lesion	11 months
Case 2	42	Male	Shaft of the Tibia	104 months	Pain, tenderness, limping, and radiographic lesion	9 months
Case 3	45	Female	Shaft of the Tibia	76 months	Pain, tenderness, limping	3 months
Case 4	42	Female	Proximal of Tibia	83 months	Pain, tenderness, radiographic lesion	8 months
Case 5	50	Male	Proximal and Shaft of Tibia	131 months	Knee Pain, tenderness, limping, knee effusion	5 months

**Figure 1.** Pre-Operative Plain Radiography of the leg Showing a big Lytic Lesion in Proximal Tibia-AP and Lateral

At the end, the cavity was filled with bone cement (PMMA) mixed with gentamicin (2 g of antibiotic per 40 g cement). Elastic bandages used for the patients and in the next day, weight bearing (WB) on extremities was commenced. Antibiotic therapy with oral Mebendazole 60 mg/kg per day started the day after surgery and continued for all the patients for six months. In search of additional lesions in other organs, we evaluated for a possible cyst in lungs or hepatobiliary system (Figure 2).

With the average 89 months follow-up, (51 to 131 months) no recurrence of disease was found in the patients. All the patients had bone cysts in the tibia bone; two cases in the proximal part of tibia, and two patients in the shaft of the bone. In one another patient both shaft and proximal part was affected. No concomitant involvement was found in other parts of body (Table 1). One of the female patients was hospitalized 73 months afterwards with diagnosis of breast cancer. She underwent mastectomy sur-

gery and radiation, but there was no bone involvement in her body related to the previous parasitic disease. One of the male patients, 72 months later, reported bilateral knee pain while walking, knee osteoarthritis was final diagnose for him. Thus, there was not any symptom of recurrence, as well (Figure 3).

3. Discussion

Iran is an endemic area for hydatid disease. It is estimated in about 1.12 in 100,000 of the Iranian population. Incidence of human hydatid disease in Khorasan area is as high as 4.45 in 100,000 (10-12). Hydatid disease of the bone, although it is not common, should always be considered in the long-term bone lytic lesions. Radiologic findings are not specific, but usually they are lytic lucent (expansile), multilocular (multi-chambered) lesion, with a reactive sclerosis rim, and a thinning cortex (13-15).

In differential diagnosis of hydatid disease of the bone, simple bone cysts, bone metastases, fibrosis dysplasia, chronic osteomyelitis, giant cells tumor, tuberculosis, and Brown tumor should be considered (16, 17). Basis of the bone hydatid disease treatment is resection surgery by removing the entire affected area plus a marginal healthy bone. Incomplete removal of the lesion will predispose further recurrence (1, 7, 8, 18).

Some surgeons prefer to fill the cavity with bone graft after resection surgery (19, 20), while some others know PMMA as the option of choice, according to several extra benefits, including heat generation effect that happens after cement polymerization. It is proposed to have necrotic and lethal effects on remained daughter cysts (21-23). Monomers and other free radicals which release during the polymerization from PMMA might be toxic for living cells (21-23). Moreover, the solidity and immediate stability following the use of cement facilitate early weight bearing without need to external support. So, we decided to use PMMA to fill defects. Additionally, irrigating cavity with hypertonic saline and Betadine was conducted to enhance removal of microscopic remained daughter cysts.

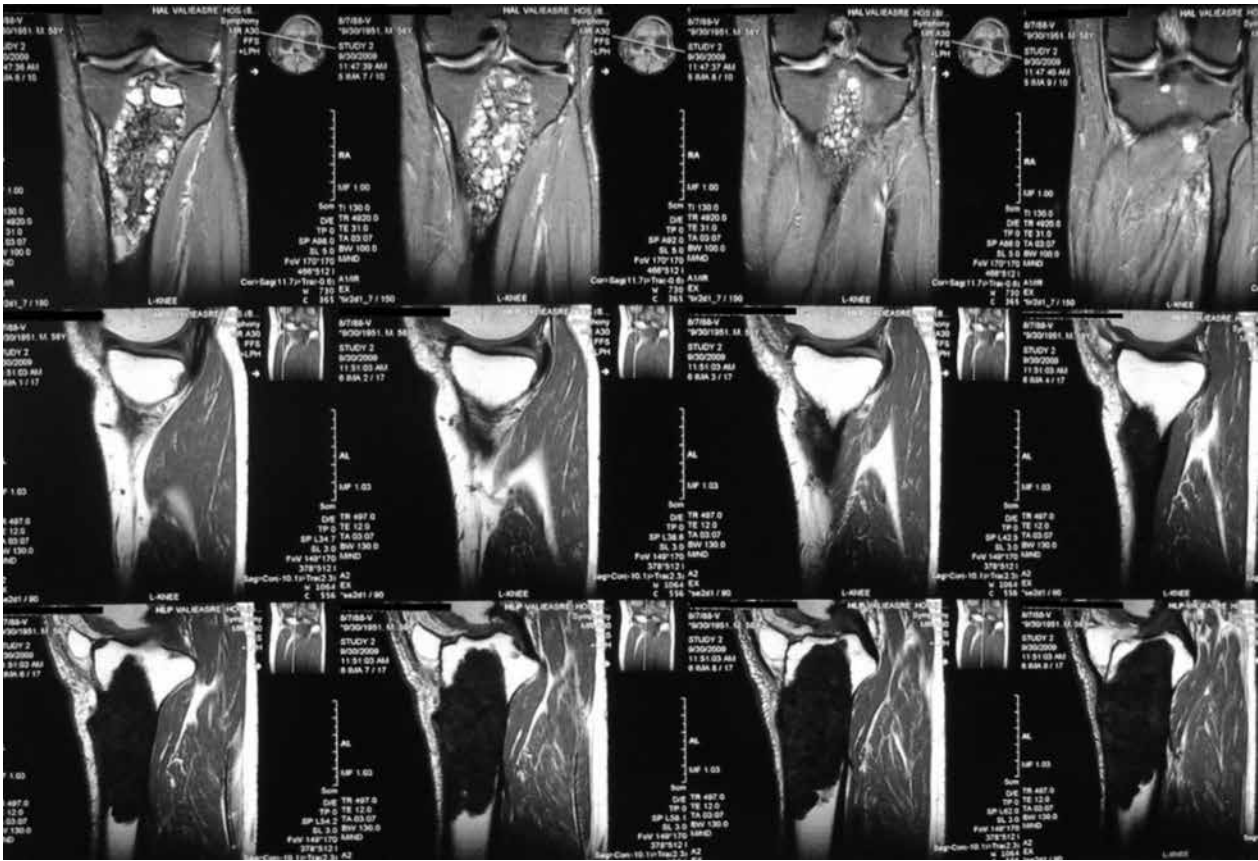


Figure 2. T1 and T2 Enhanced MRI of the leg Showing a big Hydatid Lesion in Proximal Tibia with Multiple Daughter Cysts

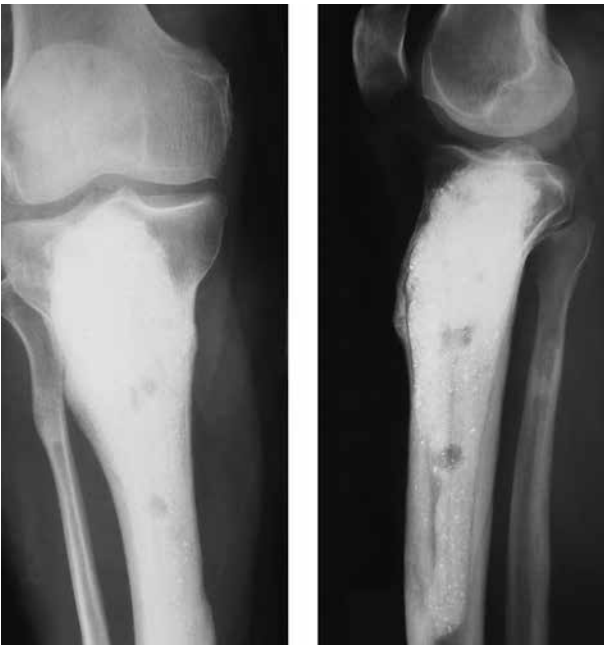

Figure 3. Post-Operative Plain Radiography of the leg-AP and Lateral

Although, there were previous reports on recurrence of lesions after 5 years in similar investigations (23), we observed no recurrence during study follow-up. It might be due to extensive and enough curettage of cavity, the use of hypertonic saline and/or continued and completed medicinal treatment by patients post-operation.

Acknowledgements

We need to appreciate Miss Nahid Mojaver, the secretary of Mashhad orthopedic and trauma research center, Shahid Kamyab Trauma Hospital for her great job in coordinating between authors and management of patient's data and follow-up sessions.

Authors' Contributions

Study concept and design: Gharehdaghi, Ebrahimzadeh, Birjandinejad and Ashraf. Analysis and interpretation of data: Gharehdaghi, Yousefi, and Rahimi shoorin. Drafting of the manuscript: Birjandinejad, Gharehdaghi and Ebrahimzadeh. Critical revision of the manuscript for important intellectual content: Rahimi shoorin, Ashraf, Birjandinejad and Yousefi.

Funding/Support

This study was observed by Vice Chancellor of research, Mashhad University of Medical Sciences without any grant.

Financial Disclosure

The funding organization, "Vice Chancellor of research, Mashhad University of Medical Sciences" is public institution and had no role in the design and conduct of the study; collection, management, and analysis of the data; or preparation, review, and approval of the manuscript.

References

- Morris BS, Madiwale CV, Garg A, Chavhan GB. Hydatid disease of bone: a mimic of other skeletal pathologies. *Australas Radiol.* 2002;**46**(4):431-4.
- Gossios KJ, Kontoyiannis DS, Dascalogiannaki M, Gourtsoyiannis NC. Uncommon locations of hydatid disease: CT appearances. *Eur Radiol.* 1997;**7**(8):1303-8.
- Savas L, Onlen Y, Akcali C, Aslan B, Pourbagher A, Tunc T, et al. Hydatid disease with atypical localization: 4 cases report. *Scand J Infect Dis.* 2004;**36**(8):613-5.
- Jellad A, Boudokhane S, Ezzine S, Ben Salah Z, Golli M. Femoral neuropathy caused by compressive iliopsoas hydatid cyst: a case report and review of the literature. *Joint Bone Spine.* 2010;**77**(4):371-2.
- Song X, Liu D, Wen H. Diagnostic pitfalls of spinal echinococcosis. *J Spinal Disord Tech.* 2007;**20**(2):180-5.
- Hooper J, McLean I. Hydatid disease of the femur. Report of a case. *J Bone Joint Surg Am.* 1977;**59**(7):974-6.
- Charles RW, Govender S, Naidoo KS. Echinococcal infection of the spine with neural involvement. *Spine (Phila Pa 1976).* 1988;**13**(1):47-9.
- Islekel S, Ersahin Y, Zileli M, Oktar N, Oner K, Ovul I, et al. Spinal hydatid disease. *Spinal Cord.* 1998;**36**(3):166-70.
- Agarwal S, Kundu ZS, Singh S, Soni N. Hydatid Disease Of The Bone. *Internet J Spine Surg.* 2009;**5**(1):240-5.
- Amouian S, Tayebi N, Mohamadian Roshan NA. Retrospective study of 1759 cases of Hydatid cyst in Mashad University hospitals. *Hakim Research Journal.* 2005;**4**(7):7-13.
- Sadjjadi SM. Present situation of echinococcosis in the Middle East and Arabic North Africa. *Parasitol Int.* 2006;**55** Suppl:S197-202.
- Yousofi H. Situation of hydatid cyst infection during last two decades (1985-2005) in Iran (Review of articles). *Shahrekord Uni Med Sci J.* 2008;**1**(10):78-88.
- Jellali MA, Zrig M, Zrig A, Mnif H, Hmida B, Abid A, et al. [Pathological humeral fracture revealing bone hydatid cyst]. *Med Mal Infect.* 2011;**41**(3):164-6.
- Moraux A, Kermarrec E, Czarniecki E, Boutry N, Demondion X, Cotten A. [Spinal infections: typical and atypical imaging features]. *J Radiol.* 2010;**91**(9 Pt 2):1049-56.
- Agarwal S, Shah A, Kadhi SK, Rooney RJ. Hydatid bone disease of the pelvis. A report of two cases and review of the literature. *Clin Orthop Relat Res.* 1992(280):251-5.
- Karray S, Zlitni M, Fowles JV, Zouari O, Slimane N, Kassab MT, et al. Vertebral hydatidosis and paraplegia. *J Bone Joint Surg Br.* 1990;**72**(1):84-8.
- Combalia A, Sastre-Solsona S. Hydatid cyst of gluteus muscle. Two cases. Review of the literature. *Joint Bone Spine.* 2005;**72**(5):430-2.
- Merkle EM, Schulte M, Vogel J, Tomczak R, Rieber A, Kern P, et al. Musculoskeletal involvement in cystic echinococcosis: report of eight cases and review of the literature. *AJR Am J Roentgenol.* 1997;**168**(6):1531-4.
- Booz MK. The management of hydatid disease of bone and joint. *J Bone Joint Surg Br.* 1972;**54**(4):698-709.
- Pintilie DC, Panoza G, Hatmanu D, Fahrner M. Echinococcosis of the humerus. Treatment by resection and bone-grafting: A case report. *J Bone Joint Surg Am.* 1966;**48**(5):957-61.
- Mjoberg B, Pettersson H, Rosenqvist R, Rydholm A. Bone cement, thermal injury and the radiolucent zone. *Acta Orthop Scand.* 1984;**55**(6):597-600.
- Rock MG. Treatment of bone cysts and giant cell tumors. *Curr opin Orthopaedic.* 1990;**1**(1):423-34.
- Yildiz Y, Bayrakci K, Altay M, Saglik Y. The use of polymethylmethacrylate in the management of hydatid disease of bone. *J Bone Joint Surg Br.* 2001;**83**(7):1005-8.