

Imatinib in Patients with Aggressive Fibromatosis and Pigmented Villonodular Synovitis: A Systematic Review

Amir Mohamad Arefpour¹, Azra Izanloo², Sam hajjaliloo Sami³, Masoud Mirkazemi^{3*}, Khodamorad Jamshidi³

¹Firrozgar Hospital, Iran University of Medical Sciences, Tehran, Iran

²Razavi Cancer Research Center, Razavi Hospital, Imam Reza International University, Mashhad, Iran.

³Bone and Joint Reconstruction Research Center, Shafa Orthopedic Hospital, Iran University of Medical Sciences, Tehran, Iran

* **Corresponding authors:** Masoud Mirkazemi, Bone and Joint Reconstruction Research Center, Shafa Orthopedic Hospital, Iran University of Medical Sciences, Tehran, Iran. Email: masoud.dr2003@gmail.com

Received 2020 November 22; Accepted 2020 April 26.

Abstract

Introduction: We undertook a systematic review of the literature to determine the efficacy and safety of Imatinib in the restriction of activity and effective treatment of patients with aggressive fibromatosis (AF) and pigmented villonodular synovitis (PVNS) and their recurrence.

Method: We searched studies in the PubMed and Cochrane collaborative library at all levels from 2010 to April 2019. Two independent reviewers evaluated the articles according to the predefined criteria and extracted the related data. Primary outcomes associated with tumor size shrinkage, relapse and overall survival along with secondary outcomes such as pain, quality of life, and side effects were investigated.

Results: 112 studies were evaluated out of which only 6 studies that covered original studies and case reports were entered into this systematic review. A total of 79 subjects had participated in these six studies with an age range of 22 to 41 years old. In five studies, participants had a primary tumor and in one research they reported relapse. The recommended dose was 400 mg/day, which was usually continued for 4 to 12 months. The tumor size shrinkage and low side effects of drugs have been reported.

Conclusion: According to the results, no systemic treatment for PVNS and AF has been approved so far, but many studies have demonstrated the efficacy of Imatinib in the treatment of these diseases. However, further studies are required for optimal treatment and combined therapies.

Keywords: Imatinib, aggressive fibromatosis, pigmented villonodular synovitis, Recurrence, Desmoids tumor, Systematic review

1. Introduction

PVNS is known as a TGCT, which is a rare synovial disease with an incidence rate of 1.8 cases per million [1-5]. Although the primary cause of PVNS is unknown at the present, recent studies have exhibited its neoplastic nature and malignancy [6-8]. This disease can affect all synovial structures, especially the knee joints. It is characterized with reproduction of synovial tissues and invasion of cartilage and bone around the joints. PVNS can produce clinical symptoms such as swelling, pain and diffuse form, or recurrence. This tumor can cause ever articular cartilage damage and functional impairment, which ultimately leads to joint replacement or even amputation [12-9]. Synovectomy, open surgery or arthroscopy is a standard treatment for PVNS [7, 13], but postoperative problems and restrictions such as long-term admission and stiffness rehabilitation periods after surgery, especially high recurrence rates, are very common. The reported postoperative recurrence rate of this disease is about 65% [10,14-15].

Imatinib is a tyrosine-kinase inhibitor, which is the selective drug for the treatment of chronic myeloid leukemia and gastrointestinal stromal cell tumors. Recent studies have revealed Imatinib clinical effects on PVNS [1, 16-19]. The effect of Imatinib on PVNS was initially reported by Blay et al. [1]. In a retrospective study, Cassier et al. treated 37 patients (74% of patients were stable) in different centers with Imatinib, reporting a recovery rate of 73% in patients [17].

However, the anti-tumor mechanism of Imatinib in PVNS and AF is unclear. Two recent studies have provided the prognosis of this rare disease. A study by Xie et al. in China, reported a recurrence risk of 20% after the first surgery [20]. Palmerini studied patients in Italy and the United States, reporting a recurrence risk of about 28% with an average follow-up of 4.8 years [21]. Various treatments have been proposed for the treatment of these tumors. In an initial adjuvant therapy, Wiss et al. suggested the use of Yttrium 90 radioactive in patients with relapsed TGCT [22]. Shabat et al. combined the debulking and

intra-articular instillation of ^{90}Y in 10 patients without any recurrence [23]. No extra-articular diffusion of ^{90}Y has also reported, but radioactive isotope injection in young patients or patients at the gestational age should be performed with caution. Some authors have reported skin necrosis or recurrent pain [24]. On the other hand, Heyd suggests that external beam radiation treatment offers a safe and effective alternative to prevent the progression or recurrence of TGCT after initial surgery. In general, the effectiveness of primary or adjuvant external beam or an intra-articular radiation as a therapeutic modality remains to be confirmed, since existing data are often limited to a small group of individuals or only one center.

This type of reports suggests that systemic therapy, though effective, may produce systemic complications that prevent the treatment of typically localized patients and non-lethal cases. Hence, the main question is whether these agents are suitable for local treatment. For this purpose, this study was designed to evaluate the efficacy and safety of Imatinib for the treatment of aggressive fibromatosis (AF) and pigmented villonodular synovitis (PVNS) and their recurrence.

Tenosynovial Gaint cell tumor (TGCT)

2. Method

2.1. Selection of studies:

The title and abstract of all papers and citations were studied by two independent reviewers (an oncology specialist and a senior medical education specialist). All disagreements were resolved by consensus.

2.2. Inclusion criteria:

All studies that investigated the efficacy of Imatinib (with varying doses or frequencies) for the treatment of patients with AF and PVNS and their recurrence, were reviewed. Studies that had addressed at least one criteria under study such as recurrence, overall survival, quality of life, general progression of the disease or side effects were included in the study.

Abstract presented at conferences, which were published in journals, but their full text was unavailable, were also included in the review. All studies that their population included patients with a tumor other than D-TGCT and AF, or children with this disease were excluded.

2.3. Sources and Search Strategies

We searched all English articles published in the Pubmed databases and Cochrane collaboration library from 2010 to April 2019. The references of papers were manually reviewed. The search strategy has been shown in Figure 1.

2.4. Data Extraction

Primary outcomes of the study were: 1. Tumor size shrinkage: Any tumor size shrinkage confirmed by MRI or PET and CT-Scan. 2- Tumor recurrence: Any reports of tumor recurrence or spread (metastasis) to other areas after treatment based on the pathology report. 3. Quality of life or overall survival of the patients in terms of being alive and absence of tumor or stability of the disease.

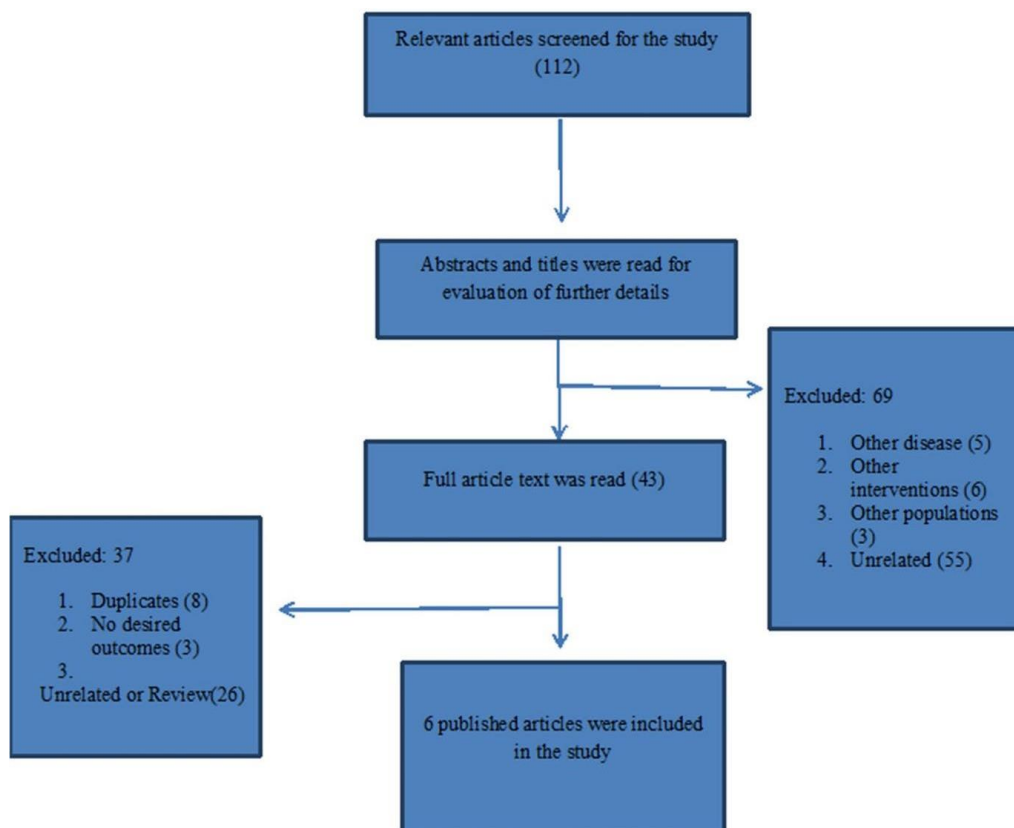


Figure 1. Search Strategy

Secondary outcomes were: 1. Pain: Assessing whether the person was deteriorating or recovering, or whether his physical activity has improved. The degree of pain measured by any valid instrument, visual analog scales or the patient's own statement were considered. 2. Side effects of Imatinib: Drug-induced toxicity or edema, fluid retention, nausea, skin rash, or any type of inflammation that was confirmed by the physician were considered as drug-induced complications, even if they did not result in the discontinuation of treatment.

3. Results

112 studies were evaluated out of which only 6 researches that consisted of original studies and case reports were entered into the systematic review.

3.1. Characteristics of Studies and Subjects

We included 6 studies in our review. The details of these studies are shown in Table 1.

There were a total of n=79 subjects in these six studies, who were in the age range of 22 to 41 years. In five studies, subjects had a primary tumor, and in one study, relapse had been reported.

Another study, which was excluded from our systematic study due to its in vitro design, was conducted by Chen in 2015 [29]. It investigated the effects of Imatinib on PVNS cell proliferation. The results of this study exhibited that Imatinib significantly inhibited the survival and invasion ability of PVNS fibroblast-like synoviocytes at a dose and a pathway associated with Z-LEHD-FMK in a specific time.

Table 1. Characteristics of Studies Include in Our Review

Article	Ravi, 2010 (25)	Kurtz, 2010 (26)	Dufresne, 2010 (27)	Cassier, 2012 (17)	Stacchiotti, 2013 (19)	Dao, 2014 (28)
Study population	N=6	N=1 (female)	N= 40	N= 29	N= 2	N= 1 (male)
Age	-	22 years old	Mean age=41 years	Mean age=41 years	24 ad 34 years old	26 years old
Drug dose	400 mg/day	400 mg/day	400 mg/day	400 mg/day and one patient 600 mg/day	400 mg/day	400 mg/day
Location and type of tumor	PVN100 knee	Aggressive fibromatosis In shoulder	70% extra abdominalaggressive fibromatosis	59% PVNS in the knee	PVNS in the knee	Recurrent tumor subscapularis muscle (AF)
Duration of treatment	7 months	34 months	12 months	4-7 months	4-7 months	--
Duration of follow-up	-	42 months	34 months	8-10 months	7 months	6 months
Improved clinical symptoms	83% improvement in pain and swelling	4 months of treatment revealed improved clinical symptoms of pain and swelling	--	73% improvement in clinical symptoms	All clinical symptoms improved	Total improvement of clinical symptoms
Quality of life or overall survival	33% stable disease	Normal condition or desirable life quality	Progressive free survival of 55% after 2 years	---	72% reduction in SUVmax	Intra tumoral calcifications reported in MRI
Tumor size shrinkage	55% reduction in PET absorption and 75% reduction in SUVmax in other imaging	MRI images reported a tumor size shrinkage.	---	74% of patients had a stable disease	Two patients with stable disease	Patient with stable disease
Relapse after treatment	7-20% re-excision	NA	8 out of 10 patients relapsed	NA	NA	NA
Side effects	Drug toxicity in one patient	NA	Not reported	Edema or fluid retention- 41%), fatigue (24%), nausea (17%), dermatosis / skin rash (10%)	Not reported	NA

Cell apoptosis was higher in the intervention group, which was blocked by the Caspase-9 inhibitor. The expression of caspase-9 was significantly elevated, and the Bcl-2 and Caspase-3 families were activated following Imatinib treatment. In general, the results showed that Imatinib had an anti-proliferation effect on PVNS-FLS and could be considered as a new treatment method.

4. Discussion

The results of the study showed that systemic therapy plays an important role in the management of unresectable diseases and the improvement of clinical and functional symptoms [1]. The key role of CSF1 in pathogenesis has led to the use of pharmaceutical drugs such as Imatinib for the treatment of PVNS / TGCT. In the same line of research, Ravi in 2011 also stressed the promising results of Imatinib in the treatment of these tumors [30]. The study of Cassier also found that Imatinib was effective in treating PVNS, but the toxicity induced by long-term drug therapy should always be considered. It has also been shown that Imatinib treatment is an effective treatment for relapsing AF tumors or c-KIT positive tumors that cannot be removed [17, 28]. However, what should be considered is the basic biological characteristics of patients that serve as a major parameter in response to Imatinib for AF treatment. These features include the KIT exon 10 M541L variant that influences tumor control. In this connection, parameters that significantly predict the therapeutic outcomes are a tumor size of more than 120 mm and lymphopenia [27]. It has been reported that Imatinib is not a suitable alternative for the treatment of nilotinib resistant PVNS tumors [19].

It is widely believed that the standard treatment for TGCT is surgery. However, D-TGCT resection is extremely difficult and it is quick to relapse even for multiple times [31]. The local malignant process of these tumors rarely leads to death, but they cause functional disorders that damage joint and impair quality of life [32].

Several studies have suggested that resection is a standard surgical treatment for TGCT, but so far no systemic treatment has been approved for D-TGCT. However, several studies have exhibited promising clinical results in relation to the use of certain medications. Also, it has been stated that systemic treatment targeting CSF1-CSF1R axis offers a suitable alternative for the young population [31]. The results of a study have shown that Imatinib therapy is appropriate for patients with desmoid tumors since FDG-PET imaging has confirmed the considerable ability of Imatinib in stabilizing tumors and slowing their growth rate [29]. This reduction even reaches as high as 54% in the standardized uptake value (SUV). Nonetheless, further research is required to validate these treatments and understand how the best of them could be combined in a therapeutic strategy.

The recommended dose is 400 mg/day and for a period of 4 to 12 months, though there is still not consensus about the appropriate duration of use.

In general, it is obvious that this drug is effective in neo-adjuvant settings, but the optimal course of treatment must be determined. The authors, based on the results, posit that in any situation, depending on the location, the

degree of tumor involvement and drug-related side effects, the behavior of the tumor may vary significantly. As a result, clinical judgment should involve determining the length of treatment, and follow-up is especially necessary to determine the long-term effects of this drug.

Given that none of the above studies were clinical trials, it is recommended to conduct clinical trials to make more informed decisions regarding the use of this drug and its effect.

Ethical and Legal Considerations: this study is review and did not need to approve by ethical committee.

Reference

- Blay JY, El Sayadi H, Thiesse P, Garret J, Ray-Coquard I. Complete response to imatinib in relapsing pigmented villonodular synovitis/tenosynovial giant cell tumor (PVNS/TGCT). *Ann Oncol* 2008; 19(4): 821-822. doi: 10.1093/annonc/mdn033.
- Gu HF, Zhang SJ, Zhao C, Chen Y, Bi Q. A comparison of open and arthroscopic surgery for treatment of diffuse pigmented villonodular synovitis of the knee. *Knee Surg Sports Traumatol Arthrosc* 2014; 22(11): 2830-2836. doi: 10.1007/s00167-014-2852-5.
- Ottaviani S, Ayrat X, Dougados M, Gossec L. Pigmented villonodular synovitis: A retrospective single-center study of 122 cases and review of the literature. *Semin Arthritis Rheum* 2011; 40(6): 546-539. doi: 10.1016/j.semarthrit.2010.07.005.
- Lavrador JP, Oliveira E, Gil N, Francisco AF, Livraghi S. C1-C2 pigmented villonodular synovitis and clear cell carcinoma: Unexpected presentation of a rare disease and a review of the literature. *Eur Spine J* 2015; 24 (Suppl 4): S465-S471. doi: 10.1007/s00586-014-3396-6.
- Myers BW, Masi AT, Feigenbaum SL. Pigmented villonodular synovitis and tenosynovitis: A clinical epidemiologic study of 166 cases and literature review. *Medicine* 1980; 59(3): 223-238. PMID: 7412554
- West RB, Rubin BP, Miller MA, Subramanian S, Kaygusuz G, Montgomery K, et al. A landscape effect in tenosynovial giant-cell tumor from activation of CSF1 expression by a translocation in a minority of tumor cells. *Proc Natl Acad Sci USA* 2006; 103(3): 690-695. DOI: 10.1073/pnas.0507321103
- Nassar WA, Bassiony AA, Elghazaly HA. Treatment of diffuse pigmented villonodular synovitis of the knee with combined surgical and radiosynovectomy. *HSS J* 2009; 5(1): 19-23. doi: 10.1007/s11420-008-9104-5
- Fiocco U, Sfriso P, Lunardi F, Pagnin E, Oliviero F, Scagliori E, et al. Molecular pathways involved in synovial cell inflammation and tumoral proliferation in diffuse pigmented villonodular synovitis. *Autoimmun Rev* 2010; 9(11): 780-784. doi: 10.1016/j.autrev.2010.07.001.
- Kaneko K, Nakahara D, Tobe M, Iwase H, Inoue Y, Ohbayashi O, et al. Pigmented villonodular synovitis of the ankle in an adolescent. *Int Orthop* 2000; 24(4): 234-237. DOI: 10.1007/s002640000141
- Park G, Kim YS, Kim JH, Lee SW, Song SY, Choi EK, et al. Low-dose external beam radiotherapy as a postoperative treatment for patients with diffuse pigmented villonodular synovitis of the knee: 4 recurrences in 23

- patients followed for mean 9 years. *Acta Orthop* 2012; 83(3): 256-260. doi: 10.3109/17453674.2012.678803.
11. Snoots WM, Watkins D, Dockery D, Mennel R, Cheek BS. Pigmented villonodular synovitis responsive to imatinib therapy. *Proc* 2011; 24(2): 134-138. doi: 10.1080/08998280.2011.11928700.
 12. Ray RA, Morton CC, Lipinski KK, Corson JM, Fletcher JA. Cytogenetic evidence of clonality in a case of pigmented villonodular synovitis. *Cancer* 1991; 67(1):121125.DOI:10.1002/10970142(19910101)67:1<121::aidcncr2820670122>3.0.co;2-p
 13. Chen WM, Wu PK, Liu CL. Simultaneous anterior and posterior synovectomies for treating diffuse pigmented villonodular synovitis. *Clin Orthop Relat Res* 2012; 470(6): 1755-1762. doi: 10.1007/s11999-012-2288-5
 14. Nakahara H, Matsuda S, Harimaya K, Sakamoto A, Matsumoto Y, Okazaki K, Tashiro Y, Iwamoto Y. Clinical results of open synovectomy for treatment of diffuse pigmented villonodular synovitis of the knee: Case series and review of literature. *Knee* 2012; 19(5): 684-687. DOI: 10.1016/j.knee.2011.12.002
 15. Nishida Y, Tsukushi S, Nakashima H, Sugiura H, Yamada Y, Urakawa H, et al. Osteochondral destruction in pigmented villonodular synovitis during the clinical course. *J Rheumatol* 2012; 39(2): 345-351. doi: 10.3899/jrheum.110730.
 16. Liu XY, Yang YF, Wu CT, Xiao FJ, Zhang QW, Ma XN, et al. Spred2 is involved in imatinib induced cytotoxicity in chronic myeloid leukemia cells. *Biochem Biophys Res Commun* 2010; 393(4): 637-642. doi: 10.1016/j.bbrc.2010.02.044.
 17. Cassier PA, gelderblom H, Stacchiotti S, Thomas D, Maki Rg, Kroep JR, et al. Efficacy of imatinib mesylate for the treatment of locally advanced and/or metastatic tenosynovial giant cell tumor/pigmented villonodular synovitis. *Cancer* 2012; 118(6): 1649-1655. doi: 10.1002/cncr.26409
 18. Ravi V, Wang WL, Lewis VO. Treatment of tenosynovial giant cell tumor and pigmented villonodular synovitis. *Curr Opin Oncol* 2011; 23(4): 361-366. doi: 10.1097/CCO.0b013e328347e1e3.
 19. Stacchiotti S, Crippa F, Messina A, Pilotti S, gronchi A, Blay JY, et al. Response to imatinib in villonodular pigmented synovitis (PVNS) resistant to nilotinib. *Clin Sarcoma Res* 2013; 3(1): 8. doi: 10.1186/2045-3329-3-8.
 20. Xie G, Jiang N, Liang C, Zeng J, Chen Z, Xu Q, et al. Pigmented villonodular synovitis: a retrospective multicenter study of 237 cases. *PLoS One* 2015; 10(3): e0121451. doi: 10.1371/journal.pone.0121451.
 21. Palmerini E, Staals EL, Maki RG, Pengo S, Cioffi A, Gambarotti M, et al. Tenosynovial giant cell tumour/pigmented villonodular synovitis: outcome of 294 patients before the era of kinase inhibitors. *Eur J Cancer Oxf Engl* 2015; 51(2):210–7. doi: 10.1016/j.ejca.2014.11.001
 22. Wiss DA. Recurrent villonodular synovitis of the knee. Successful treatment with yttrium-90. *Clin Orthop* 1982; 169:139–44. PMID:7105568
 23. Shabat S, Kollender Y, Merimsky O, Isakov J, Flusser G, Nyska M, et al. The use of surgery and yttrium-90 in the management of extensive and diffuse pigmented villonodular synovitis of large joints. *Rheumatol Oxf Engl* 2002; 41(10):1113–8. DOI:10.1093/rheumatology/41.10.1113
 24. Bickels J, Isaakov J, Kollender Y, Meller I. Unacceptable complications following intra-articular injection of yttrium 90 in the ankle joint for diffuse pigmented villonodular synovitis. *J Bone Joint Surg Am* 2008; 90(2):326–8. doi: 10.2106/JBJS.G.00441
 25. Ravi V, Wang W, Araujo DM, Ludwig JA. Imatinib in the treatment of tenosynovial giant-cell tumor and pigmented villonodular synovitis. In: *ASCO Annual Meeting*; 2010; Chicago, Illinois. *J Clin Oncol* 2010; 28:15s (suppl; abstr 10011).
 26. Kurtz J.E, Asmane I, Voegeli A.C, Neuville A, Dufresne A, Litique V, et al. A V530I Mutation in c-KIT Exon 10 Is Associated to Imatinib Response in Extraabdominal Aggressive Fibromatosis. *Sarcoma* 2010, 4. DOI; 10.1155/2010/458156
 27. Dufresne A, Bertucci F, Penel N, Le Cesne A, Bui B, Tubiana-Hulin M, et al. Identification of biological factors predictive of response to imatinib mesylate in aggressive fibromatosis. *Br J Cancer* 2010; 103(4):482- 5. doi: 10.1038/sj.bjc.6605783
 28. Dao A, Benchakroun N, Jabir H, Taleb A, Bouchbika Z, Tawfiq N, et al. Five years of local control of subscapularis aggressive fibromatosis managed by surgery and imatinib: a case report. *J Med Case Rep* 2014; 9;8:416. doi: 10.1186/1752-1947-8-416
 29. Chen K, Ren Q, Han XR, Zhang XN, Wei B, Bai XZ. Imatinib mesylate induces mitochondria-dependent apoptosis and inhibits invasion of human pigmented villonodular synovitis fibroblast-like synovial cells. *Oncol Rep* 2016; 35(1):197-204. DOI; 10.3892/or.2015.4350
 30. Ravi V, Wang WL, Lewis VO. Treatment of tenosynovial giant cell tumor and pigmented villonodular synovitis. *Curr Opin Oncol*. 2011; 23(4):361-6. doi: 10.1097/CCO.0b013e328347e1e3.
 31. Brahmi M, Vinceneux A, A. Cassie Ph. Current Systemic Treatment Options for Tenosynovial Giant Cell Tumor/Pigmented Villonodular Synovitis: Targeting the CSF1/CSF1R Axis. *Curr. Treat. Options in Oncol* 2016; 17(10). doi: 10.1007/s11864-015-0385-x.
 32. Verspoor FGM, Zee AAG, Hannink G, van der Geest ICM, Veth RPH, Schreuder HWB. Long-term follow-up results of primary and recurrent pigmented villonodular synovitis. *Rheumatol Oxf Engl* 2014; 53(11):2063–70. doi: 10.1093/rheumatology/keu230.