

Juvenile Neuronal Ceroid Lipofuscinosis in a Patient of Iranian Origin

Saeed Karimi¹, Mohsen Rezaei-moghadam¹, and Seyed Aliasghar Mosavi^{1,*}

¹ Ophthalmic Research Center, Shahid Beheshti University of Medical Sciences, Tehran, Iran

* **Corresponding author:** Seyed Aliasghar Mosavi, Ophthalmology Department, Ophthalmic Research Center, Shahid Beheshti University of Medical Sciences, Tehran, Iran. Email: a.a.mosavi@gmail.com

Received 2017 August 13; Accepted 2018 May 08.

Abstract

Introduction: Juvenile neuronal ceroid lipofuscinoses (JNCL) is a rare clinical condition especially in Asian population.

Case Presentation: We report an 8-year-old female with a history of the progressive deterioration of vision loss, mental retardation, seizures and severe physical disabilities since 3 years before admission. Fundus examination revealed bilateral optic atrophy, bull's eye maculopathy, reduced or absent electroretinogram (ERG) signals and attenuation of the retinal blood vessels. The diagnosis was confirmed by genetic detection of the mutation along with multifocal electroretinogram scans and visual evoked potential (VEP).

Conclusion: To the best of our knowledge, the current study is the first to explain a patient of Iranian origin. Consequently, although there is no treatment for the disease, genetic consults can help to prevent new affected cases from heterozygote parents.

Keywords: Electroretinogram, Juvenile neuronal ceroid lipofuscinoses, Visual evoked potential (VEP), Visual loss

1. Introduction

Neuronal ceroid lipofuscinoses (NCLs) are a group of progressive neurogenetic diseases caused by the accumulation of waxy lipopigments within the lysosomes of neurons and other cells [1]. They were expressed as the most common class of neurodegenerative diseases in children with rate of occurrence of one in 25,000 live births [1,2]. They were categorized by Wisniewski et al. [3] into four major groups based on age, histological findings, clinical presentation and genetic loci including Santavuori-Haltia disease or infantile NCL (INCL, CLN 1) caused by the deficiency in the palmitoyl protein thioesterase gene confined on chromosome 1p 323; Jansky-Bielschowsky disease or early childhood NCL (LINCL, CLN 2), mapped to chromosome 11p154, Batten disease or Juvenile NCL (JNCL, CLN 3) mapped to chromosome 16p 12.1, Kufs disease or adult NCL (CLN 4) and finally variant LINCL (vLINCL). In 20% of NCL cases, unusual forms arise that do not fit the major classic categories of neuronal ceroid lipofuscinoses [4]. Mutations that cause NCL have been found in 14 human genes since the last decade [5]. However, on the basis of newer molecular findings, they are already reclassified which have offered to be much more related to the different genetic alternatives that have before proposed by the clinical phenotypes [5,6]. We report here an 8-year-old case of JNCL and relevant issues with reference to ophthalmologic and laboratory findings are discussed.

2. Case Presentation

An 8-year-old girl, first child of first cousin was seen in our department of ophthalmology with progressive loss of vision, waning cognitive function,

motor impairment and convulsion since the age of five. She had no prenatal problems with normal birth. Her medical history was not remarkable except a history of abdominal surgery for duodenal atresia and midgut malrotation. The family pedigree revealed no other cases with problems similar to our patient. On examination, her vital signs were stable. General examination revealed Ataxia, blurred speech, drooling and perioral herpes like ulcers. Cardiac examination revealed mild PDA (Patent Ductus Arteriosus) but respiratory and abdominal system examination was normal.

On ophthalmology examination, the visual acuity was CF, "counting fingers", at 3M and 1/10 in the right (OD) and left eyes (OS), respectively. Correspondingly, manifest refraction was +0.5 -3.00 × 15 and +2.00 -2.75 × 165 in OD and OS. In the same way, intraocular pressures were 15 mmHg in OD and OS using tonopen. Anterior segment exam was normal in both eyes. Fundus was indicative of pigmentary retinopathy. Vessels were attenuated with palish optic disc. [Figure 1]. Electroretinogram (ERG) was abnormal showing severe Electroretinogram abnormalities with basically no rod-mediated activity and electronegative pattern waveforms [Figure 2]. Visual evoked potential (VEP) was also abnormal characterized by coarse enlargement of early components and mild recordable waveforms [Figure 3]. Moreover, her electroencephalogram (EEG) was abnormal in the early stages demonstrating generalized low threshold wave discharges with background slowing. The other supplementary tests including complete blood count (CBC), biochemical parameters like liver, renal, thyroid function tests and serum electrolytes were within normal limits.

She had normal developmental status until 5 years old when her problems started. The parents

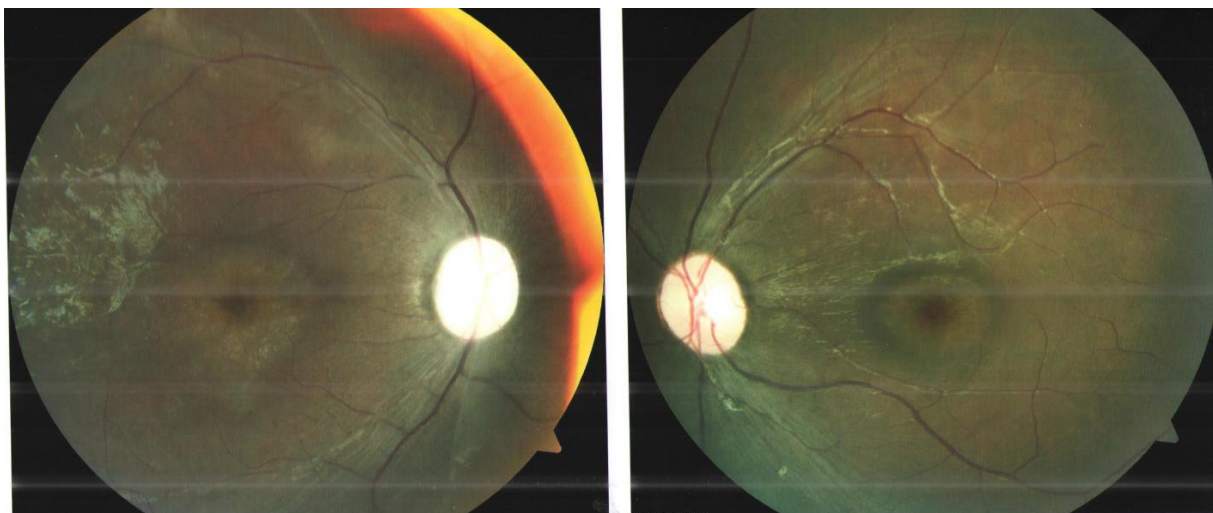


Figure 1. Fundus color revealed defective macular light reflex and optic disc pallor followed by attenuation of vessels, pigmentary retinal changes, degeneration of macula and optic atrophy

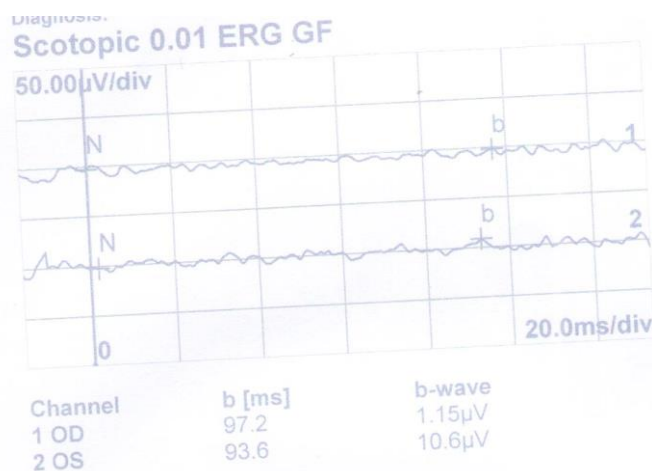


Figure 2. Electroretinogram (ERG) revealed severe ERG abnormalities with basically no rod mediated activity and electronegative pattern wave forms

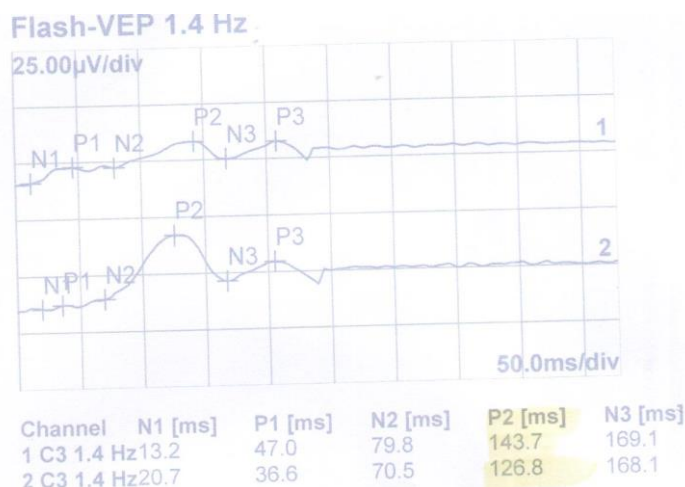


Figure 3. Visually evoked potential [VEP] shows mild recordable waveforms indicating optic nerve abnormalities and/or retinal pigmentary degeneration

noted gradual loss of vision along with declining school work for the same duration. Moreover, two years prior to admittance, she was suffering from motor impairment and ataxia which was progressively deteriorating. She could not sit without support. She also developed episodes of absence seizure attacks. Overall, significant deterioration in her behavior, cognition, and speech along with vision loss with pigmentary retinal changes and expansion of episodes of absence seizure attacks led to a strong suspicion of JNCL. The diagnosis was proved by the genetic findings of the mutation along with multifocal electroretinogram scans and visual evoked potential (VEP).

The child was given Ethosuximide 250 mg along with supportive care. Her seizure rate was reduced. Likewise, patient was investigated accordingly for other possibilities such as differential diagnosis of bull's-eye maculopathy.

3. Discussion

NCLs are a diverse group of genetically arbitrated lysosomal storage disorders taking place due to a mixture of enzymatic deficiencies which lead to accelerating neurodegeneration. Apart from adult onset NCL which is both dominant and autosomal recessive, the whole are autosomal recessive (7). In early stages, recognizing NCLs disorder is difficult due to possible alternative presentations (14). Consequently, diagnosis is habitually hindered until after the disease has progressed considerably. Additionally, differential diagnosis of a genetic basis of NCL by using symptom or disease-based gene panels proposes great assurance for supporting an early and well-timed diagnosis of NCL disease. Furthermore, early intervention is important to ensure that children with juvenile NCL disease achieve their potential. Special services that may be helpful to affected children may comprise particular remedial education, individual social support, and other social, medical and/or occupational services.

These disorders take place globally with varying incidences, even though they are more common in Scandinavians and populations of European descent; but it is rarely reported from Asian countries (7,13).

JNCL can appear as at least three different phenotypes including classic JNCL in which motor and mental symptoms occur before the age of 10; delayed JNCL comes about soon after the age of 10 but progresses less rapidly and protracted JNCL which happens later in the third and fourth decade with visual loss as the first symptom [1]. Clinically, the distinctive symptoms of JNCL comprise progressive loss of vision leading to seizures, blindness, mental retardation and motor function worsening (3). Their speech pattern is monotonous with manifests echolalia. Occasionally, dramatic visual hallucinations occur. In the final stages, intermittent bradycardia

and cardiomyopathy may occur (1).

Our case belonged to the juvenile NCL group that was presented at the age of 5 years. She initially had vision loss followed by developmental regression, gait ataxia and myoclonus. Seizures occurred later with absence seizure attacks. Ophthalmological assessment gave important hints to the identification of NCL. Generally, early ophthalmoscopic findings can arise with optic disc pallor and followed by pigmentary retinal changes, vessels attenuation, macular degeneration and optic atrophy. Similar findings were detected in our case. Moreover, in the early stages, electroretinogram was abnormal. Additionally, patients with JNCL, consistently show severe to profound ERG abnormalities with basically no rod-mediated activity and electronegative pattern (8). A similar finding was detected in our case (See figure 2). Furthermore, VEP is routinely abnormal distinguished by gross enlargement of early components. In our case, VEP study revealed mild recordable waveforms. Meanwhile, EEG findings include diffuse background slowing with occipital spikes more obvious during sleep which typify a characteristic for the diagnosis of NCL (9). In this case, generalized low threshold wave discharges were detected in EEG with pseudoperiodic discharges. The diagnosis of NCL is proved on the basis of genetic testing, enzymatic assay and histopathology (10). Correspondingly, in this case, the diagnosis was confirmed by genetic detection of the mutation. Moreover, conjunctiva, skeletal muscle, skin and rectum biopsy can be achieved for diagnosis (11).

At present, no treatment is available; however, gene therapy, bone marrow transplant and stem cell transplant have been tried but none of them have shown any long term advantage. (12). In addition, seizures are usually difficult to control; however, in this case, seizure occurrence got reduced with Ethosuximide.

In conclusion, due to lack of alertness of NCL disorders, it was rarely reported from Asian countries. Consequently, in any patients who present with progressive visual loss along with EEG and ERG features and/or psychomotor decline, genetic counseling is suggested to prevent misdiagnosis.

Acknowledgments

None.

Conflicts of interest

No author has a financial or proprietary interest in any material or method mentioned.

References

1. Zhong N. Neuronal ceroid lipofuscinoses and possible pathogenic mechanism. *Mol Genet Metab.* 2000;71(1-2):195-206. doi: [10.1006/mgme.2000.3057](https://doi.org/10.1006/mgme.2000.3057). [PubMed: [11001811](https://pubmed.ncbi.nlm.nih.gov/11001811/)].
2. Peltonen L, Savukoski M, Vesa J. Genetics of the neuronal

- ceroid lipofuscinoses. *Curr Opin Genet Dev.* 2000;**10**(3):299-305. [PubMed: [10826995](#)].
3. Wisniewski KE, Kida E, Patxot OF, Connell F. Variability in the clinical and pathological findings in the neuronal ceroid lipofuscinoses: review of data and observations. *Am J Med Genet.* 1992;**42**(4):525-32. doi: [10.1002/ajmg.1320420420](#). [PubMed: [1319116](#)].
4. Sinha S, Satishchandra P, Santosh V, Gayatri N, Shankar SK. Neuronal ceroid lipofuscinosis: a clinicopathological study. *Seizure.* 2004;**13**(4):235-40. doi: [10.1016/S1059-1311\(03\)00163-8](#). [PubMed: [15121131](#)].
5. Resource NC. A gateway for batten disease. London: University College London; 2009.
6. Worgall S, Kekatpure MV, Heier L, Ballon D, Dyke JP, Shungu D, et al. Neurological deterioration in late infantile neuronal ceroid lipofuscinosis. *Neurology.* 2007;**69**(6):521-35. doi: [10.1212/01.wnl.0000267885.47092.40](#). [PubMed: [17679671](#)].
7. Santavuori P, Heiskala H, Westermarck T, Sainio K, Moren R. Experience over 17 years with antioxidant treatment in Spielmeier-Sjögren disease. *Am J Med Genet Suppl.* 1988;**5**:265-74. [PubMed: [3146324](#)].
8. Weleber RG. The dystrophic retina in multi-system disorders: the electroretinogram in neuronal ceroid lipofuscinoses. *Eye.* 1998;**12**(3b):580-90.
9. Pampiglione G, Harden A. So-called neuronal ceroid lipofuscinosis. Neurophysiological studies in 60 children. *J Neurol Neurosurg Psychiatry.* 1977;**40**(4):323-30. [PubMed: [874509](#)].
10. Dyken PR. Neuronal ceroid-lipofuscinoses. In: Swaiman KF, editor. *Pediatric neurology principles and practice.* 3rd ed. Philadelphia: Mosby Elsevier; 1999. P. 839-46.
11. Goebel HH. Morphologic diagnosis in neuronal ceroid lipofuscinosis. *Neuropediatrics.* 1997;**28**(1):67-9. doi: [10.1055/s-2007-973672](#). [PubMed: [9151327](#)].
12. Dhar S, Bitting RL, Rylova SN, Jansen PJ, Lockhart E, Koeberl DD, et al. Flupirtine blocks apoptosis in batten patient lymphoblasts and in human postmitotic CLN3- and CLN2-deficient neurons. *Ann Neurol.* 2002;**51**:448-66. [PubMed: [11921051](#)].
13. Setty G, Saleem R, Khan A, Hussain N. Atypical juvenile neuronal ceroid lipofuscinosis: a report of three cases. *J Pediatr Neurosci.* 2013;**8**(2):117-9. doi:[10.4103/1817-1745.1](#). [PubMed: [24082928](#)].
14. Kohlschuetter A, Schulz A. CLN2 disease (classic late infantile neuronal ceroid lipofuscinosis). *Pediatr Endocrinol Rev.* 2016;**13**:682-8. [PubMed: [27491216](#)].