

Lymphoma Masquerading as Tuberculosis of the Vertebra: Case Report and Discussion of Diagnosis

Tina Shoushtarizadeh¹, Hasan Ghandehari², Masoud Mirkazemi², Behrooz Givechian², Saeed Sabbaghan^{2*}, and Azra Izanloo³

¹ Department of Pathology, Iran University of Medical Sciences, Tehran, Iran

² Bone and Joint Reconstruction Research Center, Shafa Orthopedic Hospital, Iran University of Medical Sciences, Tehran, Iran

³ Razavi Cancer Research Center, Razavi Hospital, Imam Reza International University, Mashhad, Iran

* **Corresponding author:** Saeed Sabbaghan, Bone and Joint Reconstruction Research Center, Shafa Orthopedic Hospital, Iran University of Medical Sciences, Tehran, Iran. Email: saeed.sabbaghan@gmail.com

Received 2017 May 31; Accepted 2018 May 13.

Abstract

Introduction: Mycobacterium tuberculosis is the cause of tuberculosis (TB), a serious pathogen in many parts of the world. According to the World Health Organization (WHO), one-third of the world's populations suffer from TB. Since Iran is an endemic region for TB, many practitioners have focused their attention on this issue.

Case Presentation: This study presents a patient who was misdiagnosed with TB due to the clinical symptoms of the disease and received the related treatment. But, the results of re-biopsy and immunohistochemistry tests approved the presence of Hodgkin's lymphoma in the patient.

Conclusion: In this case, the emphasis is on the differential diagnosis of Hodgkin's lymphoma of the spine and other masses. The possibility of an inflammatory process should always be considered alongside rare disorders such as lymphoproliferative to reduce the chance of putting the patient at the risk of disease progression and improper treatment course.

Keywords: Immunohistochemistry, Lymphoma, Tuberculosis

1. Introduction

As we know, tuberculosis is a common infectious disease, especially in developing countries (1,2), and it usually affects the lymphoid system and to a lesser degree, extrapulmonary systems. Clinically, TB affects lymph nodes without impacting the lung, which may be accompanied with fever, weight loss and pain or without any symptoms such as lymphoma. Given that this may lead to the diagnostic problems (3), it should be treated with caution.

In this context, this study reports a case with Hodgkin's lymphoma in the spinal cord, that was first wrongly treated as TB.

2. Case Presentation

The case was a 24-year-old man with chest pain and back pain for two months without any neurological symptoms. MRI and X-RAY were prescribed for him. After 2 months, the patient developed severe lower limb weakness and walking difficulty. Physical examination revealed bilateral lower limb weakness. Muscle Force ratio in lower limbs was 2/5 in L2, L3 and 4.5/5 in L4, L5, and S1 and DTR of heels and Achilles of lower limbs was high and sensory level was negative. In plane radiography, there was no deformity like kyphosis, but MRI images showed a mass in second thoracic vertebra and abscess formation in the anterior part of

T1-T3. (Figure 1A, B).

The patient had lost 5 kg over 2 months, and he had occasional sweating that was not nocturnal, and indicated irregular fevers. The patient's laboratory results of ESR and CRP were high. Tuberculin test was negative and there was no abnormal finding in blood count.

The patient underwent surgery immediately and posterior decompression (posterolateral Cage insertion) as well as C7 to T5 fixation were performed.

Histopathological examination of the excised tissue revealed marked infiltration of trabecular bone with chronic inflammatory cells; predominantly lymphocytes were admixed with several eosinophils. No granuloma formation was identified. No neoplastic cells were present (Figure 2). We assumed that the lesion is spondylitis although the bacterial, fungal and mycobacterial cultures were negative

According to the clinical evidences and pathological and paraclinical results (osteomyelitis), the patient was treated with four TB drugs after consultation. After 5 months, in the absence of clinical symptom improvement and high value of laboratory parameters like ESR and CRP, re-evaluation was carried out by MRI and X-RAY. The results showed that the mass had grown in its previous location with anterior mass from T1 to T3 (Figure 2). Therefore, the patient underwent posterior surgery with costotransvesectomy and sampling was performed again. Histopathological

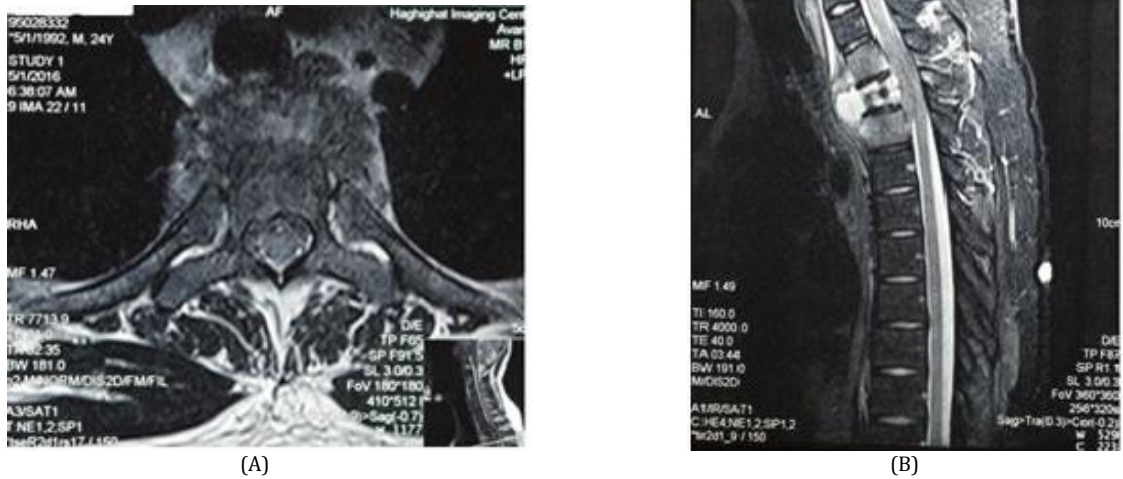


Figure 1. Preoperative MRI images

- A. Axial T1 MRI shows cortical erosions and soft tissue component that is heterogeneous
- B. T2 Sagittal MRI demonstrates T2 hypersignal lesion with cord compression and anterior soft tissue mass. Disc spaces are not involved.

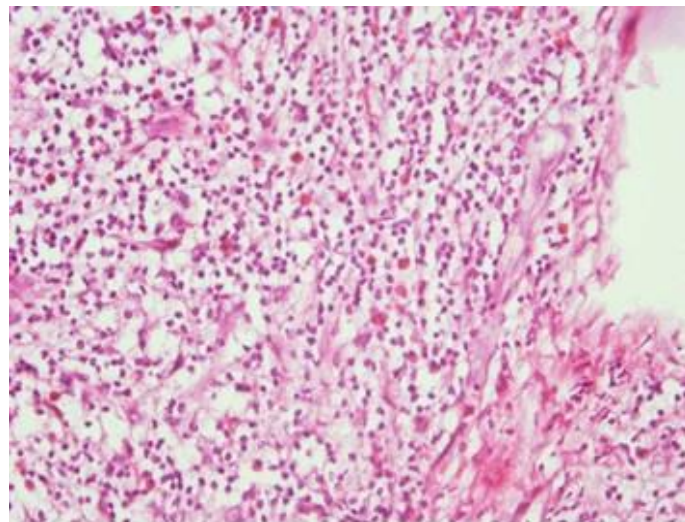


Figure 2. Diffuse infiltration of trabecular bone with lymphocytes and occasional eosinophil (Hematoxylin- Eosin. x 400)

examination of the specimen showed many atypical mononuclear cells with vesicular nuclei and prominent nucleoli in a background of mixed population of inflammatory cells including eosinophil, neutrophils and lymphocytes (figure 3). Rare Reed- Sternberg cells were noted. Occasional large cells with folded nuclei and small nucleoli were present. Immunohistochemistry study showed

immunoreactivity of the neoplastic cells for CD15, CD 30 and PAX5 (figure 4). At this time, we diagnosed the lesion as Hodgkin's disease.

Following the diagnosis, antibiotic and antituberculosis medications were stopped and the patient was treated for Hodgkin's lymphoma and after a six-month follow up, the overall health of the patient was satisfactory, and the limb forces were getting better.

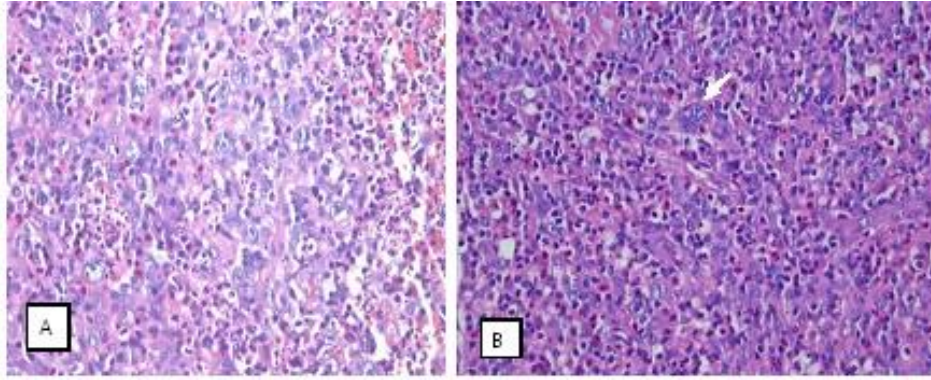


Figure 3. Many large atypical cells in a background of inflammatory cells and rare Reed- Sternberg cells (arrow) (Hematoxylin- Eosin. x 400) (A, B).

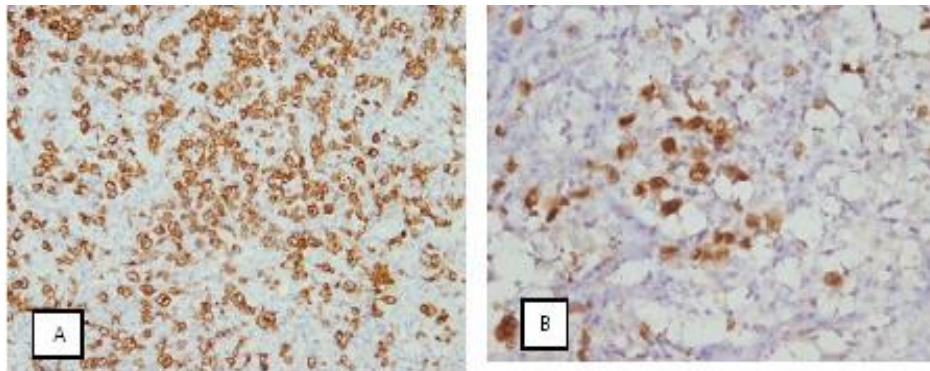


Figure 4. neoplastic cells were immunoreactive for CD15 (A) and PAX5 (B) (Immunohistochemistry, x 400).

3. Discussion

We know that the primary lymphoma of bone is about 0.5% of the whole tumors. Spinal lymphomas accounts for about 5.8% of all lymphomas (4). Isolated lymphoma in the spinal cord is rare (5). Spinal lymphoma in young people usually occur in the second and fourth decades of their life (6), which given that our case was also 24 years old, it is important to pay greater attention to the patient's age and prevalence of the disease for accurate diagnosis.

Lymphoma has various demonstrations in spine and spinal cord such as herniated spinal discs in the spine or channel. Radiological manifestations of lymphoma vary widely from a simple lytic lesion to sclerotic lesions or a combination of both. It may seem like a collapsed vertebra (7). In T1 MRI, bone marrow was normal or in form of hypointense; and in T2 images, it resembled hyperintense compared to the surrounding muscles (4). The essential feature for diagnosis of Hodgkin's disease is the presence of Reed- Sternberg cell which is a large binucleated or multinucleated cell with abundant faint acidophilic cytoplasm and sharp nuclear border. There is a large acidophilic central nucleolus. Cells without nuclear lobation are suggestive but not diagnostic for the

disease. In our patient, histopathological examination of the first specimen failed to reveal the neoplasm because of paucity of neoplastic cells and lack of Reed- Sternberg cell, but it was unmasked in the second specimen. Although the neoplastic cells were predominantly mononuclear in the latter specimen, rare Reed- Sternberg cells were noted and the diagnosis was confirmed by immunohistochemistry study. Therefore, clinical, radiologic, and histopathologic manifestations of the patient can imitate other diseases such as tuberculosis. Since the differential diagnosis of vertebra lymphoma is rare, it may include TB as well. Sandher in a study on 79 patients with bone and muscle TB reported that in 44% of the cases, TB affected the spine. (8). Moreover, the markers of CRP and ESR were also intensified in tuberculosis and lymphoma. In a 7-year-old case with primary lymphoma in the L1 vertebra, the levels of CRP and ESR reached 27.5 mg/L and 90 mm respectively after an hour (9).

There are many cases in which TB has been misdiagnosed as lymphoma. For example, Trusczyńska in 2013 reported a 59-year-old man with back pain and lower limbs impairment who was treated with chemotherapy and radiotherapy, but in the absence of recovery, he was re-examined and diagnosed with TB. With appropriate antimicrobial

therapy and sufficient rest, signs of recovery were observed gradually (4).

Meiping reported a case diagnosed with bone metastases, which was confirmed by MRI, CT, PET-CT images but the results of re-biopsy showed TB in the patient. A similar study was undertaken by Citow in which a 54-year-old woman with back pain and spinal cord compression was diagnosed with TB but due to the unsuccessful treatment, re-biopsy was performed and lymphoma was confirmed (10).

Given findings of the present study, it is important to pay further attention to accurate differential diagnosis in patients suspected with inflammatory processes of spine. The possibility of an inflammatory process should always be considered alongside rare disorders such as lymphoproliferative to reduce the chance of putting the patient at the risk of disease progression and improper treatment course.

Acknowledgments

None.

Conflicts of interest

None.

References

- Zumla A, George A, Sharma V, Herbert RH, Oxley A, Oliver M. The WHO 2014 global tuberculosis report--further to go. *Lancet Global Health*. 2015;**3**(1):e10-2. doi: [10.1016/S2214-109X\(14\)70361-4](https://doi.org/10.1016/S2214-109X(14)70361-4). [PubMed: [25539957](https://pubmed.ncbi.nlm.nih.gov/25539957/)].
- Zumla A, Raviglione M, Hafner R, von Reyn CF. Tuberculosis. *N Engl J Med*. 2013;**368**(8):745-55. doi: [10.1056/NEJMr1200894](https://doi.org/10.1056/NEJMr1200894). [PubMed: [23425167](https://pubmed.ncbi.nlm.nih.gov/23425167/)].
- Alan Selçuk N, Fenercioğlu A, Selçuk H, Uluçay C, Yencilek E. Multifoci bone tuberculosis and lymphadenitis in mediastinum mimics malignancy on FDG-PET/CT: a case report. *Mol Imaging and Radionucl Ther*. 2014;**23**(1):39-42. doi: [10.4274/Mirt.145](https://doi.org/10.4274/Mirt.145). [PubMed: [24653936](https://pubmed.ncbi.nlm.nih.gov/24653936/)].
- Truszczyńska A, Nowak-Misiak M, Rapała K, Walczak P. Tuberculosis of the spine masquerading as a spine lymphoma. A case report and discussion of diagnostic and therapeutic traps. *Neurol Neurochirur Pol*. 2013;**47**(2):189-93. [PubMed: [23650010](https://pubmed.ncbi.nlm.nih.gov/23650010/)].
- Cağavi F, Kalayci M, Tekin I, Numanoğlu G, Cağavi Z, Gül S, et al. Primary spinal extranodal Hodgkin's disease at two levels. *Clin Neurol Neurosurg*. 2006;**108**(2):168-73. doi: [10.1016/j.clineuro.2004.11.023](https://doi.org/10.1016/j.clineuro.2004.11.023). [PubMed: [16412837](https://pubmed.ncbi.nlm.nih.gov/16412837/)].
- Stoller DW, Tirman PF, Bredella MA. Pocketradiologist-musculoskeletal: top 100 diagnoses. New York: W.B. Saunders Company; 2001. P. 200-2.
- Castillo M, Midyett FA. Pocket radiologist: spine-top 100 diagnoses. *Acad Radiol*. 2002;**9**(12):1437-8. doi: [10.1016/S1076-6332\(03\)80676-1](https://doi.org/10.1016/S1076-6332(03)80676-1).
- Sandher DS, Al-Jibury M, Paton RW, Ormerod LP. Bone and joint tuberculosis. Cases in Blackburn between 1988 and 2005. *J Bone Joint Surg Br*. 2007;**89**(10):1379-81. doi: [10.1302/0301-620X.89B10.18943](https://doi.org/10.1302/0301-620X.89B10.18943). [PubMed: [17957082](https://pubmed.ncbi.nlm.nih.gov/17957082/)].
- Langley CR, Garrett SJ, Urand J, Kohler J, Clarke NM. Primary multifocal osseous Hodgkin's lymphoma. *World J Surg Oncol*. 2008;**6**:34-9. doi: [10.1186/1477-7819-6-34](https://doi.org/10.1186/1477-7819-6-34). [PubMed: [18346271](https://pubmed.ncbi.nlm.nih.gov/18346271/)].
- Citow JS, Rini B, Wollmann R, Macdonald RL. Isolated primary extranodal Hodgkin's disease of the spine: case report. *Neurosurgery*. 2001;**49**:453-6. [PubMed: [11504124](https://pubmed.ncbi.nlm.nih.gov/11504124/)].