

FDG-PET/CT Findings in a Patient with Polymyalgia Rheumatica and Accompanying Remitting Seronegative Symmetrical Synovitis with Pitting Edema

Amir Emamifar,^{1*} Soeren Hess,^{2,3} Erik Oester-Joergensen,¹ and Inger Marie Jensen Hansen^{1,3}

¹Department of Rheumatology, Odense University Hospital, Svendborg Hospital, Svendborg, Denmark

²Department of Nuclear Medicine, Odense University Hospital, Odense, Denmark

³University of Southern Denmark, Odense, Denmark

*Corresponding author: Amir Emamifar, Department of Rheumatology, Odense University Hospital, Svendborg Hospital, Svendborg, Denmark. Tel: +45-71399718, E-mail: Amir.Emamifar@rsyd.dk

Received 2016 June 29; Revised 2016 September 27; Accepted 2016 October 05.

Abstract

Background: Remitting seronegative symmetrical synovitis with pitting edema (RS3PE) is a rare, but well-defined syndrome comprising polyarthritis with symmetrical synovitis of the small joints in hands and feet accompanied by marked pitting edema. It is often considered a paraneoplastic syndrome, but here we report a case with F-18-fluorodeoxyglucose positron emission tomography/computed tomography (FDG-PET/CT) findings of polymyalgia rheumatica (PMR) in a patient with RS3PE and suspected of paraneoplastic syndrome.

Objectives: To briefly report the potential of FDG-PET/CT in rheumatic settings.

Methods: An 83-year-old male with a history of prostate adenocarcinoma simultaneously with RS3PE presented with pain and stiffness of the shoulder and hip girdles to the department of rheumatology. He was anemic and had hyperesedimentation of 106. He also complained of sore and swollen hands compatible with RS3PE. The patient had a previous course of RS3PE, presented as a paraneoplastic syndrome, together with his prostate cancer one year earlier, which resolved when the prostatic cancer was in remission. FDG-PET/CT was performed due to suspicion of repeat paraneoplastic syndrome.

Results: FDG-PET/CT findings showed no evidence of malignant disease. There was diffusely increased FDG in soft tissue around the shoulders and hips and FDG-positive axillary lymph nodes consistent with PMR.

Conclusions: RS3PE and PMR may belong to the same clinical entity. FDG-PET/CT has a potential role in the management of PMR as well as other rheumatic diseases.

Keywords: FDG-PET/CT, Polymyalgia Rheumatica, RS3PE, Paraneoplastic Syndrome, Rheumatology

1. Background

Remitting seronegative symmetrical synovitis with pitting edema (RS3PE), first described by McCarthy et al. 30 years ago, is a rare, but well-defined syndrome comprising polyarthritis with symmetrical synovitis of the small joints in hands and feet accompanied by marked pitting edema following sudden-onset inflammation (1, 2). Though the etiology of RS3PE is still unknown, infections and environmental factors have been reported to be correlated with the disease (3). It is often considered a paraneoplastic syndrome which presents frequently together with prostate, stomach and colon cancer, however in recent decades several benign etiologies have been reported, and today a common differential diagnosis is polymyalgia Rheumatica (PMR) (2, 4). Diagnosis of RS3PE is based on clinical findings and low dose steroids are the mainstay of treatment. RS3PE responds well to treatment and remains in remission for a long time unless induced by other etiology e.g. malignancy.

nancy.

PMR occurs commonly in elderly (> 50 years) and is characterized by inflammatory pain and stiffness of the shoulder and pelvic girdles together with elevation of inflammatory markers. PMR is a clinical diagnosis based on the complex of presenting symptoms and exclusion of the other potential diseases; however this poses many challenges due to a wide range of differential diagnosis. Furthermore, there is no diagnostic test which is specific for PMR. Corticosteroids are considered the treatment of choice (5).

It has suggested that PMR and RS3PE are different manifestations of the same clinical entity, or at least induced by the same mechanisms despite underlying etiology (6). The present report also points in this direction with the presence of PMR and RS3PE as well as prostatic cancer and RS3PE at the same time. F-18-fluorodeoxyglucose positron emission tomography/computed tomography's (FDG-PET/CT) impact on oncologic imaging needs no introduction, but

for suspected paraneoplastic syndromes it is only emerging as a potentially superior modality (7, 8). The same can be said for the use of FDG-PET/CT in inflammatory diseases, including rheumatologic settings, where the most frequent clinical use is in fever of unknown origin and vasculitis, but with an increasing awareness of other entities as well, e.g. rheumatic arthritis (9, 10).

2. Objectives

Employment of FDG-PET/CT for RS3PE has been reported rarely in patients with suspected malignant diseases (11). The objective of present report is to illustrate the diagnostic potential of FDG-PET/CT in rheumatic syndromes, not only when malignancies are suspected, but also when inflammatory diseases may be the inducer.

3. Methods

An 83-year-old male with a history of prostate adenocarcinoma simultaneously with RS3PE was referred to the Department of Rheumatology with pain and stiffness of the shoulder and hip girdles. He was anemic (Hemoglobin: 5.7 mmol/L, normal range: 8 - 11 mmol/L) with increased erythrocyte sedimentation rate (ESR: 106, normal range < 20). He also complained of sore and swollen hands compatible with RS3PE. Further history taking revealed a previous course of RS3PE together with his prostate cancer one year earlier. This presented as a paraneoplastic syndrome and resolved when the prostatic cancer was in remission. FDG-PET/CT imaging was performed on obvious suspicion of repeat paraneoplastic syndrome, either progression of prostate cancer or a novel, secondary cancer with accompanying RS3PE. Contrary to expectations, FDG-PET/CT findings were benign with no evidence of recurrence or bone metastasis. Instead temporal artery biopsy was performed, to diagnose a possible inflammation, which was negative. Thus, clinical findings and imaging were consistent with PMR with accompanying RS3PE and prednisolone 15 mg daily was initiated. This resulted in rapid and complete resolution of the symptoms. Prednisolone was ceased after 18 months of treatment initiation without any adverse effects.

4. Results

(Figure 1A) Maximum intensity projection whole-body FDG-PET/CT, and (Figure 1B) fused axial FDG-PET/CT scans of the shoulders and hips in a patient suspected of malignant disease due to RS3PE. There is diffusely increased FDG (circles) in soft tissue around the shoulders and hips

and FDG-positive axillary lymph nodes (arrows) consistent with PMR. To the best of our knowledge, this is the first case in the literature in which FDG-PET/CT delineated the underlying etiology of RS3PE in a benign, rheumatic setting.

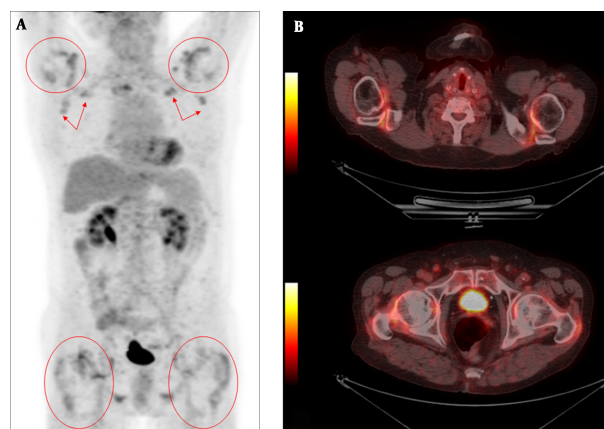


Figure 1. 1A-1B: FDG-PET/CT Findings in a PMR Patient Initially Suspected to Have Malignant Disease

5. Discussion

In conclusion, this report presented a case of RS3PE together with prostate cancer and PMR, though not at the same time, provoking thought that they belong to the same clinical entity as also suggested by previous studies (12). Additionally, this report elucidates the diagnostic potential of FDG-PET/CT in PMR and possibly in other rheumatic diseases.

Footnotes

Authors' Contribution: Amir Emamifar and Soeren Hess had equal contributions; Amir Emamifar: study concept, drafting the manuscript, revision and final acceptance of the manuscript; Soeren Hess: study concept, drafting the manuscript, revision and final acceptance of the manuscript; Erik Oester-Joergensen: study concept, revision and final acceptance of the manuscript; Inger Marie Jensen Hansen: study supervision, study concept and design, drafting the manuscript, revision and final acceptance of the manuscript.

Conflict of Interest: None declared.

Funding/Support: None declared.

References

- McCarty DJ, O'Duffy JD, Pearson L, Hunter JB. Remitting seronegative symmetrical synovitis with pitting edema. RS3PE syndrome. *JAMA*. 1985;**254**(19):2763-7. [PubMed: [4057484](#)].
- Olivieri I, Salvarani C, Cantini F. RS3PE syndrome: an overview. *Clin Exp Rheumatol*. 2000;**18**(4 Suppl 20):S53-5. [PubMed: [10948764](#)].
- Perandones CE, Colmegna I, Arana RM. Parvovirus B19: another agent associated with remitting seronegative symmetrical synovitis with pitting edema. *J Rheumatol*. 2005;**32**(2):389-90. [PubMed: [15693107](#)].
- Manger B, Schett G. Paraneoplastic syndromes in rheumatology. *Nat Rev Rheumatol*. 2014;**10**(11):662-70. doi: [10.1038/nrrheum.2014.138](#). [PubMed: [25136782](#)].
- Emamifar A, Gildberg-Mortensen R, Andreas Just S, Lomborg N, Asmussen Andreasen R, Jensen Hansen IM. Level of Adherence to Prophylactic Osteoporosis Medication amongst Patients with Polymyalgia Rheumatica and Giant Cell Arteritis: A Cross-Sectional Study. *Int J Rheumatol*. 2015;**2015**:783709. doi: [10.1155/2015/783709](#). [PubMed: [26491449](#)].
- Salvarani C, Cantini F, Olivieri I. Distal musculoskeletal manifestations in polymyalgia rheumatica. *Clin Exp Rheumatol*. 2000;**18**(4 Suppl 20):S51-2. [PubMed: [10948763](#)].
- Hess S, Blomberg BA, Zhu HJ, Hoiland-Carlsen PF, Alavi A. The pivotal role of FDG-PET/CT in modern medicine. *Acad Radiol*. 2014;**21**(2):232-49. doi: [10.1016/j.acra.2013.11.002](#). [PubMed: [24439337](#)].
- Kristensen SB, Hess S, Petersen H, Hoiland-Carlsen PF. Clinical value of FDG-PET/CT in suspected paraneoplastic syndromes: a retrospective analysis of 137 patients. *Eur J Nucl Med Mol Imaging*. 2015;**42**(13):2056-63. doi: [10.1007/s00259-015-3126-2](#). [PubMed: [26194717](#)].
- Hess S, Hansson SH, Pedersen KT, Basu S, Hoiland-Carlsen PF. FDG-PET/CT in Infectious and Inflammatory Diseases. *PET Clin*. 2014;**9**(4):497-519. doi: [10.1016/j.cpet.2014.07.002](#). [PubMed: [26050949](#)] vi-vii.
- Bjorn Kristensen S, Hess S. FDG-PET/CT in rheumatoid arthritis: A review. *Curr Mol Imaging*. 2015;**3**(3):206-10. doi: [10.2174/2211555204666150619154910](#).
- Nanni CFS. PET-CT: Rare findings and diseases berlin-heidelberg. Springer; 2012. pp. 93-5.
- Emamifar A, Hess S, Gildberg-Mortensen R, Jensen Hansen IM. Association of Remitting Seronegative Symmetrical Synovitis with Pitting Edema, Polymyalgia Rheumatica, and Adenocarcinoma of the Prostate. *Am J Case Rep*. 2016;**17**:60-4. [PubMed: [26839040](#)].