

Unilateral Sectoral Retinitis Pigmentosa in a Patient of Iranian Origin

Saeed Karimi,¹ Homayoun Nikkhah,¹ and Seyed Aliasghar Mosavi^{1*}

¹Ophthalmic Research Center, Shahid Beheshti University of Medical Sciences, Tehran, IR Iran

*Corresponding author: Seyed Aliasghar Mosavi, Ophthalmic Research Center, Shahid Beheshti University of Medical Sciences, P. O. Box: 1914853184, Tehran, IR Iran. Tel: +98-2122605915, E-mail: a.a.mosavi@gmail.com

Received 2015 December 12; Revised 2016 January 14; Accepted 2016 February 09.

Abstract

Introduction: Sectoral retinitis pigmentosa (RP) is a rare clinical condition.

Case Presentation: We present a 60-year-old female with a history of mild night blindness and decreased vision in the left eye for about 15 years.

Conclusions: Fundus examination revealed retinal pigmentary changes in the inferotemporal sector and reduced arterial caliber. In addition, fundus autofluorescence, fluorescein angiography, multifocal electroretinogram scans and electro-oculogram confirmed these clinical findings. To the best of our knowledge, the present study is the first to describe sectorial RP in the inferotemporal sector of Iranian origin.

Keywords: Sectoral, Retinitis Pigmentosa (RP), Iran

1. Introduction

Retinitis pigmentosa (RP) is a heterogeneous group of inherited retinal degenerations of the rod and cone photoreceptors (1). In various studies, the incidence is reported 1 in 4000; affecting approximately 1.5 to 2 million people worldwide (2). The most common form of RP is a cone rod dystrophy, in which visual impairment usually manifests as night blindness due to early degeneration of rods, progressive visual field loss, abnormal fundus with bone-spicule deposits and attenuated retinal vessels, diminished or absent a- and b-waves in the electroretinogram (ERG), and decrease in visual acuity once macular cones begin to degenerate (3-5). The onset of symptoms is variable that may be seen in isolation (typical RP) or may also occur as part of a syndrome as in the Bardet-Biedl and Usher syndrome. Sectoral RP is a rare variant of RP that comprises less than 2% of all RP subtypes (6, 7). The current case report describes a patient with sectoral RP in an Iranian origin patient. Correlated fundus autofluorescence imaging, fluorescein angiography (FFA), multifocal electroretinogram (mf ERG) and electrooculogram (EOG) findings are presented.

2. Case Presentation

A 60-year-old female with a history of decreased vision and mild night blindness in her left eye for about 15 years was seen in our department of ophthalmology. Her medical history was not remarkable and no history of trauma,

previous eye surgery, or any history of inflammation was detected.

The family pedigree revealed no other cases with vision problems similar to our patient. The visual acuity was 7/10 and 3/10 in the right (OD) and left eyes (OS), respectively. Correspondingly, manifest refraction was +1.5.00 -1.5.00 × 85 and -2.00 × 90 in OD and OS. In the same way, intraocular pressures were 21 and 20 mmHg in OD and OS.

Anterior segment examination was normal in both eyes. Fundus examination in left eye revealed pigment epithelial atrophy accompanied with temporal pallor, narrowing of the blood vessels in the affected segment and bone spicule hyperpigmentation suggestive of inferotemporal sectoral RP. The unaffected regions had a normal appearance. Right fundus examination disclosed no abnormalities, whereas fundus color and autofluorescence photography confirmed the presence of abnormalities in OS: clear demarcation was shown between normal and abnormal areas of the retina in fundus autofluorescence (FAF) imaging (Figure 1A - C). Fundus fluorescein angiography (FFA) (Visucam 500, Carl Zeiss Meditec, Germany) demonstrated hyper fluorescence areas due to atrophy of the retinal pigment epithelium in the RP areas. Automated Humphrey perimetry (30-2) revealed visual field defects compatible with the sectoral RP in the left eye, while the visual field in the right eye remained normal (Figure 2A). Moreover, cone-rod degeneration was detected through the absence of a- and b-waves in the electroretinogram (ERG) records along with abnormal Arden ratio in electro-

oculogram (EOG) in OS (Figure 2B - C). Furthermore, the patient was examined several times in the three years follow-up but no progression of the pathologies was detected.

3. Discussion

Sectoral RP consists of bilateral symmetrical pigmentary changes in one or two fundus quadrants (especially the lower and nasal quadrants) (6). Although ascertained diagnostic criteria of RP dictate bilateral presentation, unilateral presentations and sectoral RP have also been reported (2). The trend of sectoral RP is fixed or very slowly progressive, while generalized RP is usually progressive (6). Accordingly, to differentiate sectoral and generalized RP, close observation is necessary.

Sectoral RP is usually identified based on multifocal ERG, visual field and autofluorescence records. In our case, there were unilateral pigmentary changes involving the inferotemporal quadrants accompanied with pigment deposits in the "Bone spicule" style as well, supporting sectoral RP. On the other hand, to refine diagnosis of sectoral RP, further history was obtained: history and/or evidence of trauma, evidence of prior retinal detachment, history of intraocular foreign body, any serious systemic infection, as well as supplementary tests including a non-reactive rapid plasma regain (RPR) test, the venereal disease research laboratory (VDRL) screening test, Toxoplasmosis titers, the fluorescent Treponema antibody absorption (FTA) test, Angiotensin converting enzyme (ACE), anti-neutrophil cytoplasmic antibodies (c-ANCA and p-ANCA), purified protein derivative (PPD) test, The anti-double stranded DNA (anti-dsDNA) test and the antinuclear antibody (ANA) test that all were normal (data not shown). Moreover, no progression was detected during 3 years follow-up.

In summary, we described an unusual case of the sectoral RP in an Iranian origin patient with no progression of the pathologies at the periodic ophthalmic examinations. However, to confirm the clinical association of sectoral RP with visual outcome, more cases in tandem with genetic counseling should be provided in familial cases.

3.1. Consent

A written informed consent was obtained from the patient for publication of this case report and accompanying images.

Footnote

Authors' Contribution: Study concept and design, Saeed Karimi; acquisition of data, Saeed Karimi; analysis and interpretation of data, Homayoun Nikkhah; drafting of the

manuscript, Seyed Aliasghar Mosavi; critical revision of the manuscript for important intellectual content, Homayoun Nikkhah; statistical analysis, Saeed Karimi; administrative, technical, and material support, Homayoun Nikkhah; study supervision, Seyed Aliasghar Mosavi.

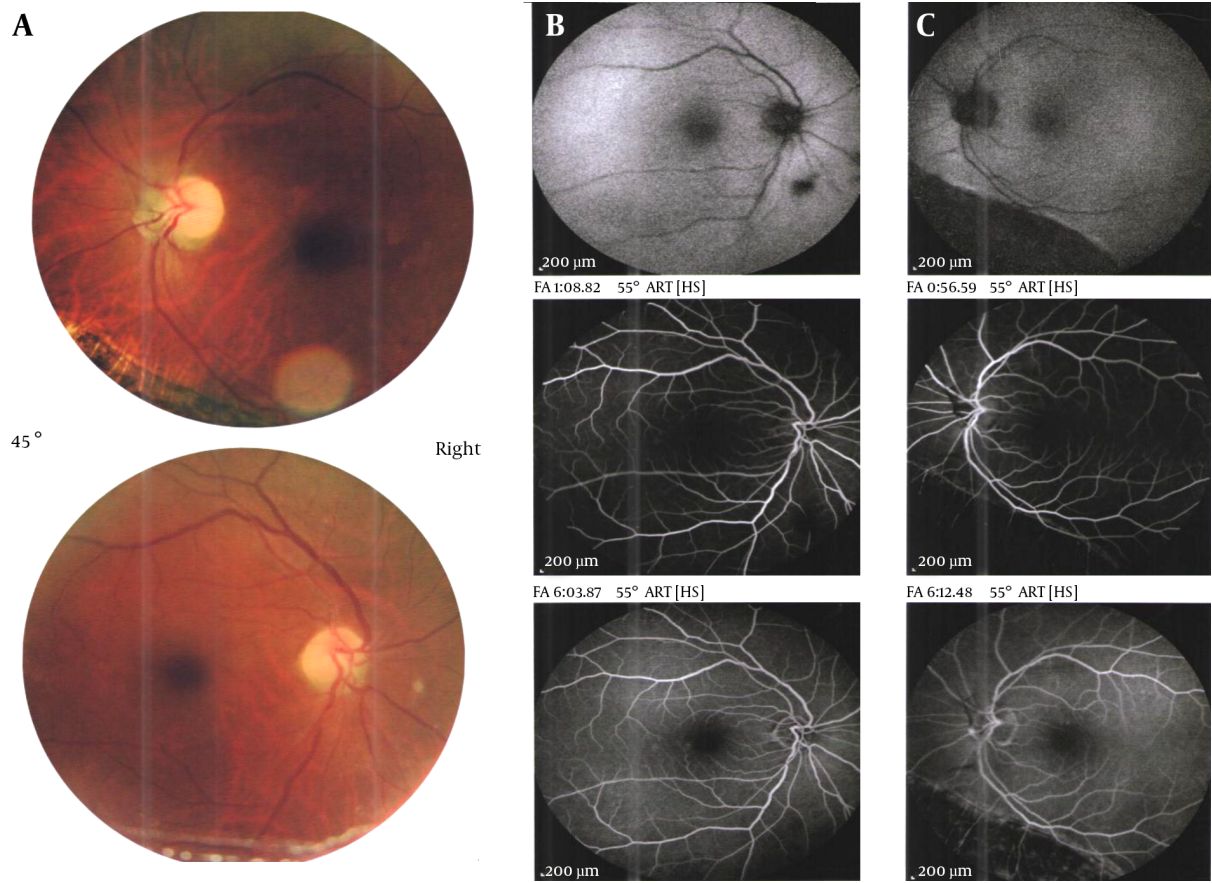


Figure 1. A, Fundus color; and autofluorescence along with early- and late-phase fluorescein angiogram of patient with unilateral sectoral retinitis pigmentosa

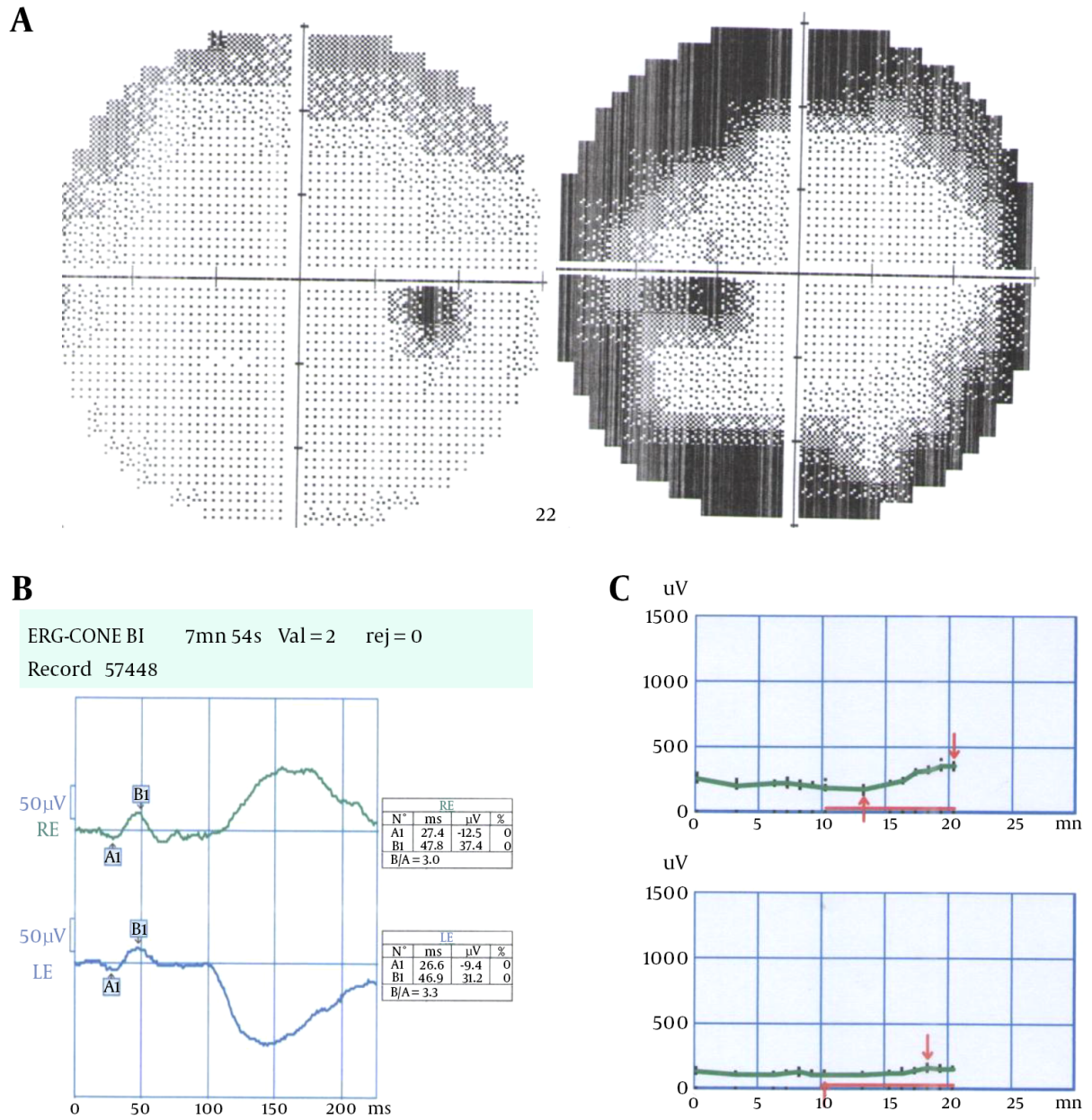


Figure 2. A, Automated Humphrey perimetry (3, 0-2); B and C, multifocal electroretinogram images and electro-oculogram (EOG) of the same patient

References

1. Ayuso C, Millan JM. Retinitis pigmentosa and allied conditions today: a paradigm of translational research. *Genome Med.* 2010;**2**(5):34. doi: [10.1186/gm155](https://doi.org/10.1186/gm155). [PubMed: [20519033](https://pubmed.ncbi.nlm.nih.gov/20519033/)].
2. Shintani K, Shechtman DL, Gurwood AS. Review and update: current treatment trends for patients with retinitis pigmentosa. *Optometry.* 2009;**80**(7):384–401. doi: [10.1016/j.optm.2008.01.026](https://doi.org/10.1016/j.optm.2008.01.026). [PubMed: [19545852](https://pubmed.ncbi.nlm.nih.gov/19545852/)].
3. Hamel C. Retinitis pigmentosa. *Orphanet J Rare Dis.* 2006;**1**:40. doi: [10.1186/1750-1172-1-40](https://doi.org/10.1186/1750-1172-1-40). [PubMed: [17032466](https://pubmed.ncbi.nlm.nih.gov/17032466/)].
4. Marmor MF. Visual loss in retinitis pigmentosa. *Am J Ophthalmol.* 1980;**89**(5):692–8. [PubMed: [7377267](https://pubmed.ncbi.nlm.nih.gov/7377267/)].
5. Grover S, Fishman GA, Alexander KR, Anderson RJ, Derlacki DJ. Visual acuity impairment in patients with retinitis pigmentosa. *Ophthalmology.* 1996;**103**(10):1593–600. [PubMed: [8874431](https://pubmed.ncbi.nlm.nih.gov/8874431/)].
6. Scholl HP, Kremers J. L- and M-cone driven large-field and multifocal electroretinograms in sector retinitis pigmentosa. *Doc Ophthalmol.* 2003;**106**(2):171–81. [PubMed: [12678282](https://pubmed.ncbi.nlm.nih.gov/12678282/)].
7. Fulton AB, Hansen RM. The relation of rhodopsin and scotopic retinal sensitivity in sector retinitis pigmentosa. *Am J Ophthalmol.* 1988;**105**(2):132–40. [PubMed: [3341429](https://pubmed.ncbi.nlm.nih.gov/3341429/)].