

# Autoimmune Progesterone Dermatitis With Angioedema Caused by Exogenous Progesterone in a Pregnant Woman: A Case Report

Mohsen Salari Rad,<sup>1</sup> Ehsan Bolvardi,<sup>1,\*</sup> and Sima Salari Rad<sup>2,3</sup>

<sup>1</sup>Department of Emergency Medicine, Mashhad University of Medical Sciences, Mashhad, IR Iran

<sup>2</sup>Department of Psychiatry, Tabriz University of Medical Sciences, Tabriz, IR Iran

<sup>3</sup>Honorary Fellow Research, Aberdeen Biomedical Imaging Centre, Aberdeen University, Aberdeen, UK

\*Corresponding author: Ehsan Bolvardi, Department of Emergency Medicine, Mashhad University of Medical Sciences, Mashhad, IR Iran. Tel: +98-9155157813, E-mail: BolvardiE@mums.ac.ir

Received: May 25, 2015; Revised: June 13, 2015; Accepted: July 22, 2015

**Introduction:** Autoimmune progesterone dermatitis (APD) is an uncommon immunologic condition accompanied with dermatologic manifestations and caused by an immune response to endogenous or exogenous progesterone in women during their reproductive years. We report a case of APD in a pregnant woman who received exogenous progesterone to prevent preterm delivery.

**Case Presentation:** A 28-year-old female who was 17 weeks pregnant was referred to the emergency department with the complaint of progressive edema in the dorsal side of her right hand and progressive dyspnea. Intradermal skin test using 50 mg/mL progesterone resulted in 15 mm wheal in the injected area and approved the diagnosis of APD.

**Conclusions:** Patients with APD may have very different symptoms requiring immediate care; therefore, being informed about this condition is necessary for the physicians in emergency and obstetrics and gynecology departments. Also a positive history of such condition in a pregnant woman necessitates precautions in the management of her pregnancy due to the potential of anaphylactic events.

**Keywords:** Autoimmune Progesterone Dermatitis; 17-alpha-hydroxyprogesterone; Pregnant

## 1. Introduction

APD which is first defined by Géber (1) in 1921 is a rare dermatologic condition usually caused by an immune response to endogenous or exogenous progesterone in women during their reproductive years.

This uncommon condition is associated with various skin manifestations such as urticaria, eczema, folliculitis and angioedema (2, 3). The condition is often described by the recurrence of dermatologic manifestations in the luteal phases of the menstrual cycle (4). Also, some cases reported progression to anaphylactic reactions and; therefore, they introduced the term progesterone induced anaphylaxis for this rare condition (5-8).

Suggestion of an autoimmune basis for these conditions relies on positive skin tests to progesterone, reproduction of symptoms with intramuscular hormonal changes, and detection of purified antibodies to progesterone (3).

Although most APD cases were the results of endogenous progesterone during the luteal phases of menstrual cycles, very few iatrogenic APD cases were also reported in the literature (9). We present a unique case of iatrogenic APD in a pregnant woman who had received 17-alpha-hydroxyprogesterone caproate (17p), a metabolite of progesterone, to prevent premature delivery.

## 2. Case Presentation

A 28-year-old female who was 17 weeks pregnant was referred to the emergency department of Imam Reza Hospital located in Northeast of Iran, complaining of progressive edema in the dorsal side of her right hand and progressive dyspnea. The patient was referred to the obstetrics and gynecology department the previous day, complaining of spotting. She underwent progesterone supplement therapy to prevent preterm delivery by receiving 17-alpha-hydroxyprogesterone caproate. At arrival, vital signs were evaluated and showed stable values including: axillary temperature 36.8°C, pulse rate 80/min, respiratory rate 17/min, blood pressure 110/65 mmHg and oxygen saturation of 95%.

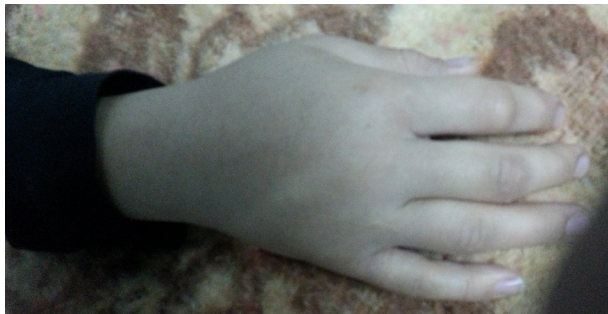The accessory respiratory muscles of the patient did not function properly and a mild generalized wheezing was heard in lung auscultation. Jugular vein pulse was not elevated and the patient did not have any complaints of abdominal pain. Moderate swelling of right hand was present as well as facial and throat swelling. Moreover, erythema was present in the pharynx. The patient had experienced similar symptoms during her menstrual cycles in the past but, with milder signs and symptoms.

The patient was admitted and underwent careful observations. Hand edema progressed gradually (Figure 1) along

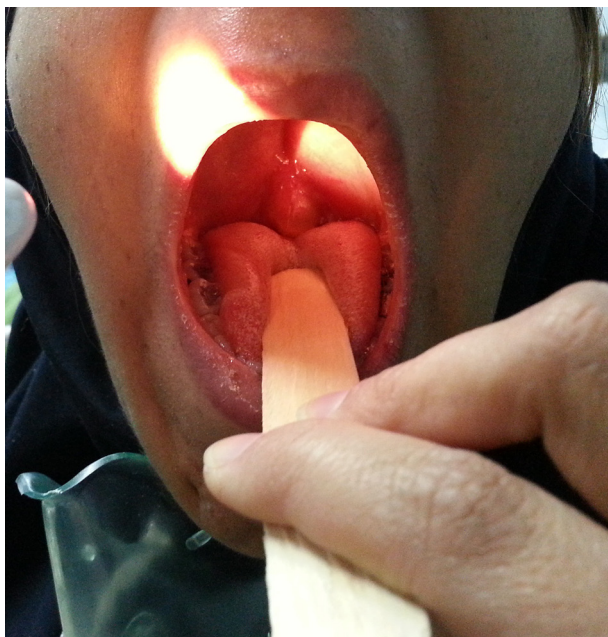
with increased erythema and swelling of uvula (Figure 2). Abdominal discomfort was also added to her complaints. The respiratory rate increased to 28/min; therefore, 0.3 mg epinephrine was administered intradermally to the patient which resulted in the resolution of symptoms.

Para-clinical evaluations including complete blood count, blood urea nitrogen, creatinine, arterial blood gas (ABG) and urine analysis did not show any abnormal values. With clinical suspicion to APD, an intradermal skin test using 50 mg/mL progesterone was performed which resulted in 15 mm wheal in the injected area while the control saline revealed no skin erythema or wheal.

According to the results described above and based on the diagnostic criteria proposed by Warin (10), the patient was diagnosed with APD. After symptom resolution, the patient remained under observation but the symptoms did not return and due to stable and normal health condition, the patient was discharged with the prescription of Prednisolone 50 mg and ranitidine 150 mg tablets for one week.



**Figure 1.** Moderate Swelling of Right Hand



**Figure 2.** Erythema and Swelling of Uvula

### 3. Discussion

APD is not a common disorder, and in the majority of cases, the autoimmune phenomenon is caused by endogenous progesterone production. Progesterone is produced by the corpus luteum and it has been shown that it reaches its maximum in the blood stream between the 20<sup>th</sup> and 21<sup>st</sup> day of the menstrual cycle that describes why most women with APD experienced dermatologic lesions in the luteal phase of their menstrual cycles (11). Dermatologic manifestations observed in APD include pruritus, urticaria, erythema multiform, eczema, angioedema and other popular and vesicular lesions and in few cases, mucosal lesions such as oral colic ulcerations were associated with skin manifestations as well (12).

Most reported cases of APD were due to endogenous progesterone but some cases including our patient demonstrate iatrogenic APD due to the administration of exogenous progesterone for therapeutic reasons (9,13). Although the administration of "17-alpha-hydroxyprogesterone" for preventing preterm labor was the main reason of APD in our patient, she also had a history of previous APD cycles during her menstruation but with minor symptoms.

Pathogenesis of APD is still remained unclear (14). The multiple dermatologic manifestations and various test results made it difficult to propose an exact pathogenesis for this condition.

Some studies stated that progesterone can stimulate type 2 helper T cells (TH2) and cause an allergic reaction. Furthermore, it is stated that direct effect of progesterone on mast cells and basophils can induce antibody responses (3). Moreover, it has been suggested that previous exposure to exogenous progesterone could induce hypersensitivity to endogenous progesterone and lead to APD. However, there have been reported patients with no history of hormone therapy (12, 14, 15). Another mechanism suggested for sensitization to progesterone is steroid cross sensitivity which is demonstrated by Meltzer et al. (16). Besides, it is proposed that a raised level of progesterone during menstrual cycle or pregnancy could reach a critical level resulted in autoimmune reactions by the woman's body (17).

in this case, the presented patient, the increase of progesterone during pregnancy did not cause the autoimmune reaction while the administration of exogenous progesterone led to APD and angioedema in a previously progesterone sensitized patient.

It is also important to mention that several different patterns of symptoms were observed during pregnancy in women with APD. Some reported progesterone sensitive rash and some even reported spontaneous abortions and worsened dermatologic lesions while others reported improvement of APD symptoms during pregnancy (6, 15, 18-22). Therefore, various manifestations of APD during pregnancy imply on the existence of multiple mechanisms for the pathogenesis of this

condition. Since our case showed that the exogenous administration of progesterone in such women can lead to life threatening situations such as angioedema and anaphylaxis which would be very serious specially in a pregnant woman, it is very important to pay excessive care to pregnant women who had previous history of cyclic dermatologic lesions during their menstrual cycles and need hormonal therapy during their pregnancy for any reason.

The diagnosis of APD requires a detailed history of previous attacks accompanied by an intradermal progesterone injection test. It should be regarded that an aqueous suspension or aqueous alcohol solution of progesterone is better to be used since progesterone in oil can cause an irritant reaction. Moreover, due to the possible risk of precipitating a severe anaphylaxis, the skin test must be carried out by experienced physicians and with caution in a well prepared clinic (2).

To perform the skin test for our patient, we used progesterone in aqueous solution at a concentration of 50 mg/dL which was also used in similar studies (2, 3). Reaction to progesterone skin test could be immediate or delayed; therefore, 24 - 48 hours must be considered in order to achieve the best interpretation (23).

In the recent years to confirm the immunologic pathogenesis of APD, further tests and analyses including circulatory antibodies to progesterone, basophil granulation tests, direct and indirect immunofluorescence to luteinizing cells of the corpus luteum and circulatory antibodies to 17- $\alpha$ -hydroxyprogesterone were introduced (2). However, due to the unreliability of these tests, they are not widely employed yet.

Due to the various symptoms of APD, different treatments were used. Conventional antihistamine therapy is not beneficial and in some cases the symptoms are resolved spontaneously. Systemic glucocorticoids such as prednisolone showed to be effective if control of a single APD reaction is desirable (3). Nevertheless, for the long term treatment of APD, inhibition of endogenous progesterone secretion by the suppression of ovulation is commonly used. To achieve this suppression, 17- $\alpha$ -alkylated steroids such as danazol or stanozolol have been used (24).

Desensitization using progesterone was also tried which was not beneficial. Moreover, in the past conjugated estrogens were used but because of their potential role in malignancy, their usage is abandoned (3).

Patients with APD show various dermatological manifestations. Since the pathogenesis of APD is not well defined, its diagnosis and choice treatment are unclear as well. Therefore, being informed about this condition is necessary for the physicians in emergency and obstetrics and gynecology departments. Positive history of this condition in a pregnant woman necessitates precautions in the management of her pregnancy due to the potential of anaphylactic events.

## Acknowledgements

The authors would like to thank Department of Emergency Medicine, Mashhad University of Medical Sciences for providing the facilities of the study and Farhad Fathi Moghadam for writing assistance.

## Authors' Contributions

Diagnosis the case, study concept, design and drafting of the manuscript: Mohsen Salari Rad, critical revision of the manuscript for important intellectual content: Ehsan Bolvardi and Sima Salari Rad. Study supervision and corresponding author: Ehsan Bolvardi.

## References

- Géber H. Some information about the pathology of urticaria menstruationalis, [in German]. *Dermatology*. 1921;**32**(2-3):143-50.
- Baptist AP, Baldwin JL. Autoimmune progesterone dermatitis in a patient with endometriosis: case report and review of the literature. *Clin Mol Allergy*. 2004;**2**(1):10.
- Snyder JL, Krishnaswamy G. Autoimmune progesterone dermatitis and its manifestation as anaphylaxis: a case report and literature review. *Ann Allergy Asthma Immunol*. 2003;**90**(5):469-77.
- Bolaji I, O'Dwyer EM. Post-menopausal cyclic eruptions: autoimmune progesterone dermatitis. *Eur J Obstet Gynecol Reprod Biol*. 1992;**47**(2):169-71.
- Brooks GG. Anaphylactoid shock with medroxyprogesterone acetate: A case report. *J La State Med Soc*. 1974;**126**(11):397-9.
- Meggs WJ, Pescovitz OH, Metcalfe D, Loriaux DL, Cutler GBJ, Kaliner M. Progesterone Sensitivity as a Cause of Recurrent Anaphylaxis. *Obstet Gynecol Surv*. 1985;**40**(6):372-3.
- Slater J, Kaliner M. Effects of sex hormones on basophil histamine release in recurrent idiopathic anaphylaxis. *J Allergy Clin Immunol*. 1987;**80**(3):285-90.
- Slater JE, Raphael G, Cutler GJ, Loriaux DL, Meggs WJ, Kaliner M. Recurrent anaphylaxis in menstruating women: treatment with a luteinizing hormone-releasing hormone agonist—a preliminary report. *Obstet Gynecol*. 1987;**70**(4):542-6.
- Bandino JP, Thoppil J, Kennedy JS, Hivnor CM. Iatrogenic autoimmune progesterone dermatitis caused by 17 $\alpha$ -hydroxyprogesterone caproate for preterm labor prevention. *Cutis*. 2011;**88**(5):241-3.
- Warin AP. Case 2. Diagnosis: erythema multiforme as a presentation of autoimmune progesterone dermatitis. *Clin Exp Dermatol*. 2001;**26**(1):107-8.
- Kakarla N, Zurawin RK. A case of autoimmune progesterone dermatitis in an adolescent female. *J Pediatr Adolesc Gynecol*. 2006;**19**(2):125-9.
- Dedecker F, Graesslin O, Quereux C, Gabriel R, Salmon-Ehr V. Autoimmune progesterone dermatitis: a rare pathology. *Eur J Obstet Gynecol Reprod Biol*. 2005;**123**(1):120-1.
- Jenkins J, Geng A, Robinson-Bostom L. Autoimmune progesterone dermatitis associated with infertility treatment. *J Am Acad Dermatol*. 2008;**58**(2):353-5.
- Rodenas JM, Herranz MT, Tercedor J. Autoimmune progesterone dermatitis: treatment with oophorectomy. *Br J Dermatol*. 1998;**139**(3):508-11.
- Schoenmakers A, Vermorken A, Degreef H, Dooms-Goossens A. Corticosteroid or steroid allergy? *Contact Dermatitis*. 1992;**26**(3):159-62.
- Meltzer L. Hypersensitivity to gonadal hormones. *South Med J*. 1963;**56**:538-42.
- George R, Badawy SZ. Autoimmune progesterone dermatitis: a case report. *Case Rep Obstet Gynecol*. 2012;**2012**:757854.
- Bierman SM. Autoimmune progesterone dermatitis of pregnancy. *Arch Dermatol*. 1973;**107**(6):896-901.
- Farah FS, Shbaklu Z. Autoimmune progesterone urticaria. *J Allergy Clin Immunol*. 1971;**48**(5):257-61.
- Georgouras K. Autoimmune progesterone dermatitis. *Australas J*

- Dermatol.* 1981;**22**(3):109-12.
21. Leech SH, Kumar P. Cyclic urticaria. *Ann Allergy.* 1981;**46**(4):201-3.
22. Hart R. Autoimmune progesterone dermatitis. *Arch Dermatol.* 1977;**113**(4):426-30.
23. Brestel E, Thrush L. The treatment of glucocorticosteroid-dependent chronic urticaria with stanozolol. *J Allergy Clin Immunol.* 1988;**82**(2):265-9.
24. Shahar E, Bergman R, Pollack S. Autoimmune progesterone dermatitis: effective prophylactic treatment with danazol. *Int J Dermatol.* 1997;**36**(9):708-11.