

Outcomes of Surgical Treatment of Pediatric Supracondylar Humerus Fractures by Bilateral Triceps Approach

Hassan Rahimi Shourin¹; Mohammad Halaj Moghadam¹; Mohammad Gharehdaghi^{1*}; Alireza Hootkani¹; Masoud Mirkazemi¹; Majid Tajpour¹; Mahmood Tavousidoroh¹; Maryam Asadian²

¹Department of Orthopedic Surgery, Imam Reza Hospital, School of Medicine, Mashhad University of Medical Sciences, Mashhad, IR Iran

²Orthopedic and Trauma Imam Reza Research Center, Faculty of Medicine, Mashhad University of Medical Sciences, Mashhad, IR Iran

*Corresponding author: Mohammad Gharehdaghi, Department of Orthopedic Surgery, Imam Reza Hospital, School of Medicine, Mashhad University of Medical Sciences, Mashhad, IR Iran. Tel/Fax: +98-5118595023, E-mail: gharahdaghim@mums.ac.ir

Received: May 6, 2014; Revised: July 7, 2014; Accepted: July 23, 2014

Background: Humerus supracondylar fracture is one of the most common elbow injuries. Choice of treatment depends on grading of the displacement. Closed Reduction and pinning is the preferred method of treatment. Open reduction is indicated when we encounter neurovascular injury after closed reduction. One of the most important factors in the outcome of surgery is an appropriate approach that would provide better exposure with less soft tissue injury. Anterior, posterior, medial and lateral surgical approaches are used for this type of fracture.

Objectives: Posterior bilateral triceps approach has less been studied so far. In this study we review the results of humerus supracondylar fracture surgery by this approach.

Patients and Methods: This study is a case series and includes 43 patients aged between 3.5-15 who referred to Imam Reza Hospital in Mashhad Iran from July 2006 to October 2011 with humeral supracondylar fracture; Gartland; type III. All patients had at least once, failed closed reduction. On admission, all patients with open fracture or neurovascular injury were excluded. All the patients were operated in one hospital and with the same method (bilateral triceps open reduction). Patients were followed up from 7 months to 2 years by the clinicians who were not involved in the selection of patients, the process of treatment and surgery. History, basic information, DASH questionnaire (disability of the arm and hand) physical clinical examination, particularly ROM (range of motion) and objective tests to measure muscular strength and radiographies were reviewed.

Results: The mean age was 7.2 ± 2.4 years. The mechanisms of injuries were falling in 25 patients, skateboarding accident in 6 patients and 12 cases of motorized or non-motorized vehicle accidents. 8 patients required physiotherapy (maximum 20 sessions). Joint ROM in 91% of patients was complete. 4 patients (9%) had about 5-10 degree of limited range of extension (flexion deformity). The mean elbow flexion and extension strength in the injured hand was 80%-95% of the opposite one. No instability and laxity of the elbow joint was seen. The mean score of DASH was 30 ± 2.4 . Reduction in the X-ray control after surgery was acceptable. No loss of reduction, nonunion and malunion, hardware failure, wound and infection complications, bleeding from the wound or hematoma formation at the site of surgery, neurological disorders after surgery and paresis were seen in postoperative examinations.

Conclusions: By using Bilateral triceps approach for humerus supracondylar fracture, you can be able to have a very good exposure field as presented on pictures and due to less soft tissue damage in this approach, you need less immobilization time. After six weeks, the patient has full elbow range of motion, acceptable DASH score and no complication.

Keywords: Pediatrics; Humerus; Fractures, Bone

1. Background

Humerus supracondylar fracture is one of the most common elbow injuries and approximately includes 16.6 % of all fractures in child hood (1) and 95% of the cases are extension type (2). 5-30% of these fractures are associated with vascular and neural injury (3-6). Basically choice of treatment depends on the grade of displacement (7) and the preferred method of treatment is Closed Reduction and pinning (8-10). The indication of Open Reduction in cases of closed reduction is the occurrence of neurovascular injuries simultaneously. Anterior, posterior, medial and lateral surgical approaches are used for this type of

fracture surgery (7). To prevent compartment syndrome and vascular complications in this type of fracture, emergency treatment is recommended (1, 3, 11-15). However, recent studies have suggested that delay in treatment does not affect the outcome (16-19). Some studies have been done on the results of the surgery that are mostly based on the radiographic outcome with the surgeon's evaluation about the success of the surgery. To achieve more accurate evaluation, it is better to use the questionnaires, clinical exam, objective and subjective tests by clinicians who are not engaged on investigation. Obviously one of

the most important factors in the outcome of surgery is an appropriate approach that has sufficient exposed field with less soft tissue damage. Sufficient exposure during supracondylar fracture surgery is critical for viewing fracture components and proper reduction. Most of surgeons believe that the best exposure means that you can access to supracondylar columns and the articular surface in posterior approach (20-24). This approach requires restoring the extensor mechanism of the elbow through splitting triceps muscle or olecranon osteotomy which has its own complications. Posterior bilateral triceps has less been studied so far.

2. Objectives

Our objective in this study is to evaluate the results of this approach.

3. Patients and Methods

This study includes 43 patients aged between 4-15 that referred to Imam Reza Hospital in Mashhad, Iran from July 2006 to October 2011 with humeral supracondylar fracture Gartland type III. 29 patients were boys and 14 were girls. The mean average was 7.2 (3.5-15 years old). All the fractures were Gartland type III. All patients with concomitant open fracture or neurovascular injuries were excluded on admission. Patients were evaluated in terms of radiography and mechanism of injury and they were examined completely. All fractures were treated in one hospital and only by two surgeons. And only bilateral triceps approach was used. Followed up period was from 7 months to 2 years. Main follow up items were included ROM (range of motion) and DASH (disability of the arm and hand) questionnaire and objective tests for measuring muscular strength. DASH questionnaire consists of 30 questions with high sensitivity and validity and based on patients' responses (25, 26). On imaging, the presence of bridging callus over and between fractured fragments indicates the union.

On anteroposterior x-ray, if the diaphyso-metaphysal differs from normal 7 degrees of valgus, the varus and valgus deformity is defined; and if on lateral view the angle between capitohumeral differs from 20-45 degrees, it is misaligned (considering normal 30° anterior angulation) (27).

3.1. Surgical Technique

For all of the 43 patients, we used posterior bilateral triceps surgery. In this procedure, patients are placed in lateral decubitus position of the opposite side and the elbow is hung in the flexion position on one side. As the same as posterior midline approach, the skin incision and subcutaneous tissue is made from 7 cm upper to 2 cm lower than the olecranon. Subcutaneous arteries were coagulated; subcutaneous tissues were dissected off the triceps muscle and fascia without splitting the muscle (Figure 1). The ulnar nerve is explored and safely

preserved during the operation. Then the triceps muscle is dissected off the both sides of humerus and along the intermuscular septum, then the posterior surface of distal humerus is deperiosteated. Therefore, all the regions of medial and lateral epicondyle, condyle and supracondylar ridge and joint surface are exposed (Figure 1) and the proximal part is exposed as much as the surgeon needs. In this approach, we do not need to cut the triceps mechanism. Meanwhile, for exposing the articular surface, there is no need to olecranon osteotomy. Fixation after reduction was done by lateral and medial pin or only by two pins in lateral (epicondyle) (Figure 2).

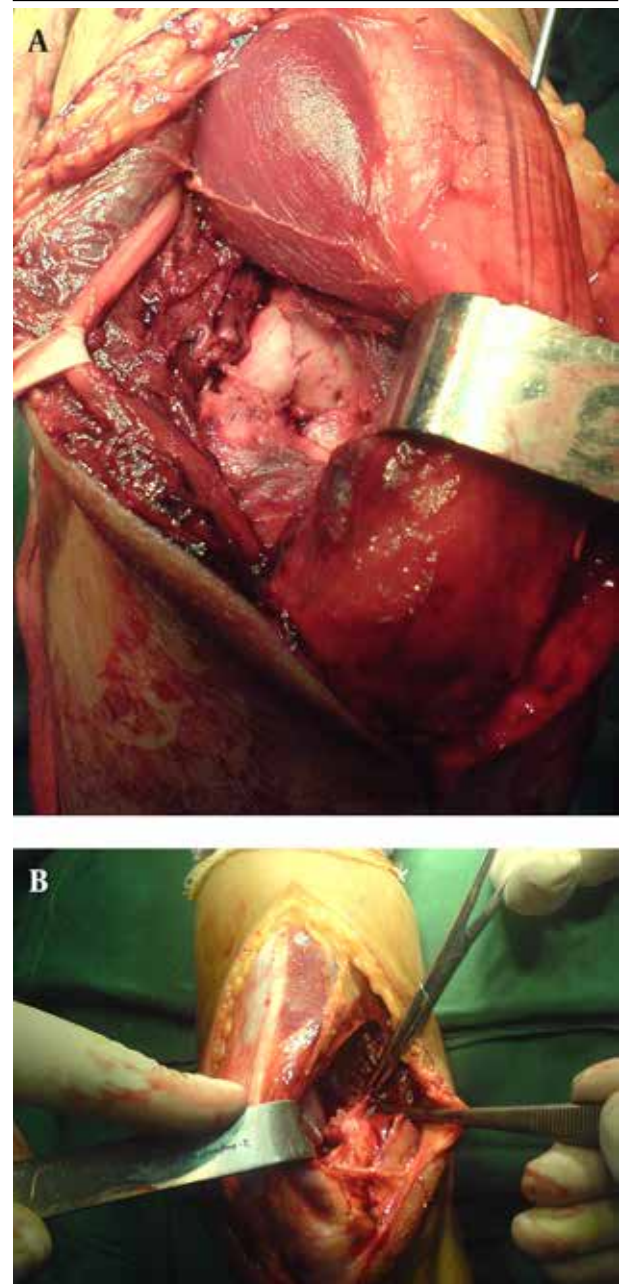


Figure 1. A Six- Year-Old Girl With Supracondylar Humerus Fracture Was Surgically Treated by Bilateral Triceps Approach

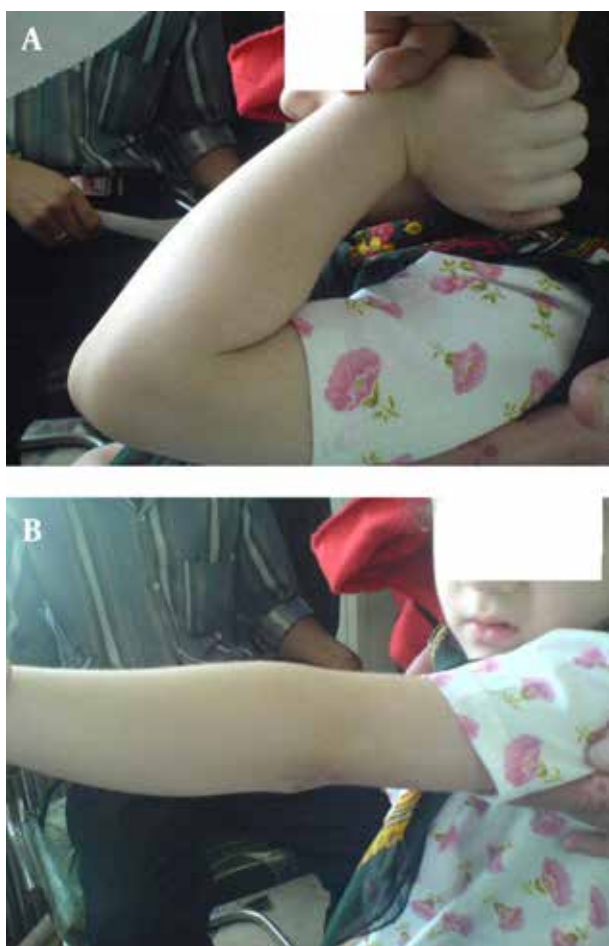

Figure 2. Three Weeks After Surgery, Patient Achieved Full Flexion and Extension in Elbow Joint

After surgery, the muscle was released to the primary site and there was no need to repair fascia or muscle. After insertion of the drain, skin and subcutaneous tissue were restored. Half an hour before and 24 hours after surgery, 3 doses of intravenous antibiotic, first-generation of cephalosporin type, were administered and the organ was immobilized for 2 weeks (with splint). Active assisted flexion and extension movements started after 2 weeks, and we removed the splints (3-6 weeks) by x-ray control after solid union.

3.2. Assessment

Patients were followed up from 7 months to 24 months by the clinicians who were not involved in the process of treatment and in choosing the patients for surgery. History, clinical examination, evaluation of ROM and radiographies, tests to measure muscular strength and controlling the filling out of questionnaire were done by these people. All data were stored in a data bank. For each patient, the healthy hand is considered as a control. All data were analyzed by SPSS software. To compare muscle strength and ROM in both hands the Paired t-test was used.

4. Results

43 patients that were suffering from humerus supracondylar fracture, Gartland type III, and were operated by posterior approach (bilateral triceps) had 7 to 24 months follow up. The mean age was 7.2 (from 3.5 to 15 years old). 29 patients were boys and 14 were girls (2:1). The mechanism of injury in 25 patients (58%) was falling down (including accidents during play or exercise), in 6 patients (14%) was accident during skateboarding and in 12 patients (28%) was having an accident with a motorized or non-motorized vehicle. None of the patients had preoperative disorder. 1.2 of the patients were reported to have pulse disorder but cf and pulse oximetry were normal and no signs of organ ischemia were observed and there was no need for vascular surgery. In all patients the surgery was done through this procedure from 12 to 72 hours after the injury (all patients had at least one failed closed reduction). None of the patients was infected in site of surgery or pin site and osteomyelitis.

4.1. Range Of Motion (ROM)

Period of immobilization after surgery was 2 weeks that at the end of the second week, active assisted and then active movement therapy were allowed to patients. For 8 patients physiotherapy was administered (up to 20 sessions) and the rest (81.5%) did not receive any physiotherapy. In 91% of the patients (39 patients), ROM was complete (0-120°). 4 patients (9%) had the limited range of 5-10 degree with flexion contracture 5-10°. Rotation of the forearm in all patients was normal and equal to the opposite organ.

4.2. Muscle Strength

The mean strength of elbow flexion in the injured hand was 80%-94% of the opposite hand. The mean strength of elbow extension at angles of 45-90 degree was 82%-90% of the opposite hand.

4.3. Stability

No cases of instability and laxity in elbow joint were reported in stress examinations of elbow joint, either in valgus or varus stress test or anterior and posterior drawer.

4.4. DASH

When DASH = 0, it shows the normal state and when DASH = 100, it shows the severe impairment of the upper extremity. The mean score of DASH in our patients was reported 15 ± 2.4 and it did not change during the frequent examinations. Meanwhile 4 patients who did not fill out DASH questionnaire completely were excluded from this part of the study. Except in this case, no significant relation was reported between the age and DASH score ($P \geq 0/5$).

4.5. Radiographic Union Assessment

Post-operative radiographies showed acceptable reductions. No deviation was reported from the acceptable standard (27). In lateral view, relative extension limitation (flexion deformity of the elbow, 5-10 degree) was observed only in 5 patients and no unacceptable varus angulation was reported. Lat and AP views showed equal gap or gap < 1 mm in 3 patients and step of about 1mm in 14 patients. Loss of reduction was observed in none of the patients. Bone union occurred in 41 patients from 4 to 8 weeks and no non union and mal union were reported during follow up period. In 2 patients who were suffering from metaphyseal and diaphyseal fractures, radiologic union appeared after 11 weeks.

4.6. Complications

Rate of bleeding from drain site was less than 100 cc in all cases. No bleeding from lesion or hematoma at the site of the surgery was reported in any of the patients and no hardware failure was observed. In all patients, end of the fixation pins were kept out of the skin, and removing the pins did not lead to any complications such as lesion or infection. In all the patients, pins were removed from 4 to 6 weeks. No postoperative neurological disorder was reported in any of the patients and no paresis was found in the immediate examinations after the surgery and during the follow up (FIU) period. Mean duration of the surgery after inflating the tourniquet was 30 minutes (from 20 to 40 minutes) using the clock on the wall.

5. Discussion

In our study, the relative mean age of the patients was 7.2 and the ratio of boy to girl was 2:1, and it was similar to other studies (28, 29). Manual muscle test along with the clinical examination have been offered so far to assess the muscle strength, but the accuracy of this procedure is less than the objective assessment by using a device (2, 4, 30-33). However, according to the study conducted by McKee et al. (27), evaluation of the muscle strength has yielded more favorable results in our study than the posterior approach (triceps-splitting) or olecranon osteotomy. We believe that one of the main reasons resulting in favorable outcome of the surgery is applying an approach which has the minimum damage and provides the best exposure for reduction and fixation. Most researches have shown that the posterior approach is the favorite one (20-24), and bilateral triceps approach has the benefit of posterior wide exposure plus minimal soft tissue injury. Meanwhile, other approaches including anterior, medial or lateral fail to expose distal humerus widely; therefore, it is not easy to observe the whole fracture site and get satisfactory reduction of a fracture (27).

Since the result of muscle strength test in our study is more favorable than the other studies (34, 35) and there is a similarity between the assessment results of DASH scale in our study and other studies using the current ap-

proaches (25-27, 36) and also there is a similarity between the rate of complications such as duration of surgery, rate of union and determining final ROM in our study and others; we suggest bilateral triceps posterior approach rather than other approaches. Finally other supplementary and comparative studies both in case and control groups are suggested.

Acknowledgements

The authors thank the Vice Chancellor for Research of Mashhad University of Medical Sciences, Mashhad, Iran for technical supports. Authors also know it is necessary to appreciate Mrs. Najmeh Jafari Moghaddam for her helps in revising and submitting the manuscript.

Authors' Contributions

Study concept and design: Hassan Rahimi Shourin, Mohammad Halaj Moghadam, Alireza Hootkani and Mohammad Gharehdaghi; analysis and interpretation of data: Masoud Mirkazemi, Mahmood Tavousidoroh, Majid Tajpour and Maryam Asadian; drafting of the manuscript: Masoud Mirkazemi, Majid Tajpour, Mahmood Tavousidoroh, and Maryam Asadian; critical revision of the manuscript for important intellectual content: Mohammad Gharehdaghi, Mohammad Halaj Moghadam, Alireza Hootkani and Hassan Rahimi Shourin.

Funding/Support

This study was observed by Vice Chancellor of Research, Mashhad University of Medical Sciences without any grant.

References

1. Cheng JCY, Shen WY. Limb fracture pattern in different pediatric age groups: a study of 3,350 children. *J Orthop Trauma*. 1993;7(1):15-22.
2. Chen RS, Liu CB, Lin XS, Feng XM, Zhu JM, Ye FQ. Supracondylar extension fracture of the humerus in children. Manipulative reduction, immobilisation and fixation using a U-shaped plaster slab with the elbow in full extension. *J Bone Joint Surg Br*. 2001;83(6):883-7.
3. Brown IC, Zinar DM. Traumatic and iatrogenic neurological complications after supracondylar humerus fractures in children. *J Pediatr Orthop*. 1995;15(4):440-3.
4. Campbell CC, Waters PM, Emans JB, Kasser JR, Millis MB. Neurovascular injury and displacement in type III supracondylar humerus fractures. *J Pediatr Orthop*. 1995;15(1):47-52.
5. Schoenecker PL, Delgado E, Rotman M, Sicard GA, Capelli AM. Pulseless arm in association with totally displaced supracondylar fracture. *J Orthop Trauma*. 1996;10(6):410-5.
6. Shaw BA, Kasser JR, Emans JB, Rand FF. Management of vascular injuries in displaced supracondylar humerus fractures without arteriography. *J Orthop Trauma*. 1990;4(1):25-9.
7. Mangwani J, Nadarajah R, Paterson JM. Supracondylar humeral fractures in children: ten years' experience in a teaching hospital. *J Bone Joint Surg Br*. 2006;88(3):362-5.
8. Nacht JL, Ecker ML, Chung SM, Lotke PA, Das M. Supracondylar fractures of the humerus in children treated by closed reduction and percutaneous pinning. *Clin Orthop Relat Res*. 1983(177):203-9.
9. Agus H, Kalenderer O, Kayali C. Closed reduction and percutaneous pinning results in children with supracondylar humerus

- fractures. *Acta Orthop Traumatol Turc.* 1999;**33**:18–22.
10. Pirone AM, Graham HK, Krajchich JL. Management of displaced extension-type supracondylar fractures of the humerus in children. *J Bone Joint Surg Am.* 1988;**70**(5):641–50.
11. Gerardi JA, Houkom JA, Mack GR. Pediatric update #10. Treatment of displaced supracondylar fractures of the humerus in children by closed reduction and percutaneous pinning. *Orthop Rev.* 1989;**18**(10):1089–95.
12. Farnsworth CL, Silva PD, Mubarak SJ. Etiology of supracondylar humerus fractures. *J Pediatr Orthop.* 1998;**18**(1):38–42.
13. Flynn JC, Matthews JG, Benoit RL. Blind pinning of displaced supracondylar fractures of the humerus in children. Sixteen years' experience with long-term follow-up. *J Bone Joint Surg Am.* 1974;**56**(2):263–72.
14. Walloe A, Egund N, Eikelund L. Supracondylar fracture of the humerus in children: review of closed and open reduction leading to a proposal for treatment. *Injury.* 1985;**16**(5):296–9.
15. Mehserle WL, Meehan PL. Treatment of the displaced supracondylar fracture of the humerus (type III) with closed reduction and percutaneous cross-pin fixation. *J Pediatr Orthop.* 1991;**11**(6):705–11.
16. Gupta N, Kay RM, Leitch K, Femino JD, Tolo VT, Skaggs DL. Effect of surgical delay on perioperative complications and need for open reduction in supracondylar humerus fractures in children. *J Pediatr Orthop.* 2004;**24**(3):245–8.
17. Mehlman CT, Strub WM, Roy DR, Wall EJ, Crawford AH. The effect of surgical timing on the perioperative complications of treatment of supracondylar humeral fractures in children. *J Bone Joint Surg Am.* 2001;**83-A**(3):323–7.
18. Leet AI, Frisancho J, Ebrahimzadeh E. Delayed treatment of type 3 supracondylar humerus fractures in children. *J Pediatr Orthop.* 2002;**22**(2):203–7.
19. Iyengar SR, Hoffinger SA, Townsend DR. Early versus delayed reduction and pinning of type III displaced supracondylar fractures of the humerus in children: a comparative study. *J Orthop Trauma.* 1999;**13**(1):51–5.
20. Bryan RS, Morrey BF. Extensive posterior exposure of the elbow. A triceps-sparing approach. *Clin Orthop Relat Res.* 1982(166):188–92.
21. Bryan RS, Morrey BF. Fractures of the distal humerus. In: Morrey BF editor. *In The Elbow and Its Disorders.*. Philadelphia: W. B. Saunders; 1985. pp. 302–39.
22. DeLee JC, Green DP, Wilkins KE. Fractures and dislocations of the elbow. In: Rockwood CA, Green DP editors. *In Fractures in Adults.*. Philadelphia: J. B. Lippincott; 1984. pp. 559–652.
23. Kasser JR, Richards K, Millis M. The triceps-dividing approach to open reduction of complex distal humeral fractures in adolescents: a Cybex evaluation of triceps function and motion. *J Pediatr Orthop.* 1990;**10**(1):93–6.
24. McKee M, Jupiter J, Toh CL, Wilson L, Colton C, Karras KK. Reconstruction after malunion and nonunion of intra-articular fractures of the distal humerus. Methods and results in 13 adults. *J Bone Joint Surg Br.* 1994;**76**(4):614–21.
25. Hudak PL, Amadio PC, Bombardier C. Development of an upper extremity outcome measure: the DASH (disabilities of the arm, shoulder and hand) [corrected]. The Upper Extremity Collaborative Group (UECG). *Am J Ind Med.* 1996;**29**(6):602–8.
26. Turchin DC, Beaton DE, Richards RR. Validity of observer-based aggregate scoring systems as descriptors of elbow pain, function, and disability. *J Bone Joint Surg Am.* 1998;**80**(2):154–62.
27. McKee MD, Wilson TL, Winston L, Schemitsch EH, Richards RR. Functional outcome following surgical treatment of intra-articular distal humeral fractures through a posterior approach. *J Bone Joint Surg Am.* 2000;**82-A**(12):1701–7.
28. Celiker O, Pestilci FI, Tuzuner M. Supracondylar fractures of the humerus in children: analysis of the results in 142 patients. *J Orthop Trauma.* 1990;**4**(3):265–9.
29. Landin LA. Fracture patterns in children. Analysis of 8,682 fractures with special reference to incidence, etiology and secular changes in a Swedish urban population 1950–1979. *Acta Orthop Scand Suppl.* 1983;**202**:1–109.
30. Otsuka NY, Kasser JR. Supracondylar Fractures of the Humerus in Children. *J Am Acad Orthop Surg.* 1997;**5**(1):19–26.
31. Kurer MH, Regan MW. Completely displaced supracondylar fracture of the humerus in children. A review of 1708 comparable cases. *Clin Orthop Relat Res.* 1990(256):205–14.
32. Reitman RD, Waters P, Millis M. Open reduction and internal fixation for supracondylar humerus fractures in children. *J Pediatr Orthop.* 2001;**21**(2):157–61.
33. *National Confidential Enquiry into Patient Outcome and Death 1995–96 report. Who operates when? 2004.* Available from: http://www.ncepod.org.uk/2004report/PDF_chapters/Overview_Chapter.pdf.
34. Waddell JP, Hatch J, Richards R. Supracondylar fractures of the humerus—results of surgical treatment. *J Trauma.* 1988;**28**(12):1615–21.
35. McKee MD, Jupiter JB. Trauma to the adult elbow and fractures of the distal humerus. In: Browner BD, Jupiter JB, Levine AM, Trafton PG editors. *Skeletal Trauma: Fractures, Dislocations, Ligamentous Injuries.*. Philadelphia: W. B. Saunders; 1998. pp. 1455–522.
36. Ware JE, Snow KK, Kosinski M, Gandek B. *SF-36 Health Survey Manual and Interpretation Guide.* Boston: New England Medical Center, The Health Institute; 1993.