

Ovarian Hyper Stimulation Syndrome in Two Spontaneous Pregnancies

Nezhat Mousavifar¹; Marzieh Ghasemi²; Leili Hafizi^{3,*}; Amirreza Reihani⁴

¹Department of Infertility and IVF, Faculty of Medicine, Montaserieh Hospital, Mashhad University of Medical Sciences, Mashhad, IR Iran

²Department of Obstetrics and Gynecology, Faculty of Medicine, Khatamolanbia Hospital, Zahedan University of Medical Sciences, Zahedan, IR Iran

³Women Health Research Center, Department of Obstetrics and Gynecology, Faculty of Medicine, Imam Reza Hospital, Mashhad University of Medical Sciences, Mashhad, IR Iran

⁴School of Medicine, Mashhad University of Medical Sciences, Mashhad, IR Iran

*Corresponding author: Leili Hafizi, Women Health Research Center, Department of Obstetrics and Gynecology, Faculty of Medicine, Imam Reza Hospital, Mashhad University of Medical Sciences, Ebnesina Street, Mashhad, IR Iran. Tel: +98-5118022608, Fax: +98-5118525305, E-mail: hafizil@mums.ac.ir

Received: August 15, 2013; **Revised:** October 24, 2013; **Accepted:** November 2, 2013

Introduction: Ovarian hyper stimulation syndrome (OHSS) occurs mainly after excessive stimulation of the ovaries by exogenous gonadotropin administered in the context of ovulation induction and in vitro fertilization procedures (iatrogenic OHSS). Spontaneous OHSS is a rare event. Such cases would explain other etiologies except ovulation induction. In this case report, we have presented two cases of OHSS in spontaneously conceived pregnancies.

Case Presentation: In this case report, we are going to present two cases of OHSS occurring in spontaneously conceived pregnancies. One of the patients mentioned the history of this syndrome in her sister, and the other one confronted with this syndrome in her second pregnancy. Both of them referred to the hospital with typical symptoms and signs of OHSS. They did not have Polycystic Ovary Syndrome (PCOS) and any other problem in pregnancy. Thrombophilia workup, Tumor markers, renin-aldosterone and thyroid function tests were normal.

Discussion: The presence of OHSS in spontaneous pregnancy especially in familial pattern may lead us to evaluate some endogenous pathogenic factors.

Keywords: Female; Adult; Pregnancy; Case Reports

1. Introduction

Ovarian hyper stimulation syndrome (OHSS) is a condition characterized by enlarged multicystic ovaries associated with the abdominal distension and discomfort. In some cases, it is associated with ascites, pleural/pericardial effusion, electrolytic imbalance, coagulation disorder and, if not treated adequately, it may be fatal (1, 2). The characteristic feature of the ovarian hyper stimulation syndrome is an increase in capillary permeability resulting in a fluid shift from the intravascular to extra vascular spaces (3, 4), probably mediated by the increased ovarian secretion of vasoactive substances including vascular endothelial growth factor, elements of the renin-angiotensin system, and other cytokines (5, 6). OHSS is mainly an iatrogenic complication of induction of ovulation (7-9).

In rare cases, however, it presents in the absence of any treatment at the beginning of a spontaneous pregnancy (8, 9). Some theories have been suggested about the etiology of such cases such as mutation in the follicle, stimulation hormone receptor (9, 10), or presentation of some specific conditions like hypothyroidism (11, 12) or pituitary adenoma (13). So, the report of these cases can help to improve the exact cause of spontaneous OHSS. The two cases of spontaneous OHSS are described below.

Such rare cases may propound some endogenous factors as pathogenesis of this disease.

2. Case Presentation

2.1. The First Patient

A 17-year-old woman was referred to the Department of Obstetrics and Gynecology of Imam Reza Hospital, Mashhad University of Medical Sciences due to the severe abdominal distention and mild dyspnea of two-week duration, at about 10 weeks of gestation. She had been admitted for 3 days in a hospital in another city one week ago. Then, because of unexplainable conditions she referred to this tertiary care hospital.

She was primigravida and the pregnancy was occurred without any medication. Her menses had been regular without any history of hirsutism or other androgenic symptoms, so she did not have PCOS symptoms. Also, she did not have any problem in conceiving. There was no report of autoimmune and hormonal diseases in her past medical history. There was no report of infertility in her family history. But her sister had been admitted about

Implication for health policy/practice/research/medical education:

Although OHSS is usually an iatrogenic complication of ovulation induction, it can also occur spontaneously without any evidence of endocrinological disorders. Describing such cases may reveal new etiological predisposing factors.

Copyright © 2014, Razavi Hospital; Published by Kowsar Corp. This is an open-access article distributed under the terms of the Creative Commons Attribution License, which permits unrestricted use, distribution, and reproduction in any medium, provided the original work is properly cited.

three years ago in a hospital with the same complain at about 9.5 weeks of gestation and she had undergone a laparotomy and ovarian cystectomy. Her operation report showed bilateral multi cystic ovarian cysts.

Physical findings of the patient at the referral examination were: severe abdominal distention with diffuse tenderness. Pelvic ultrasonography showed multilobulated bilateral ovarian masses extending to the umbilicus with ascites (estimated to be about 500 cc). The diameter of the right ovary was reported as 105 × 50 mm and the left ovary as 90 × 60 mm. Uterus contained a gestational sac with normal decidual reaction and a 10-week singleton alive fetus (Figure 1).

Hemoglobin and hematocrit values were 13.7 mg/dL and 38%, respectively. The serum Albumin level was 2.8 gr/dL. All other parameters including routine liver and kidney function tests were normal. The thyroid function test, Anti cardiolipin antibody (IgG, IgM), Lupus anticoagulant and ANA were analyzed and reported normal. CA125 value found to be in the normal range, aldosterone and plasma rennin activity values were reported normal. Thrombophilia workup including factor V Leiden, pro C and S activity, homocystein and antithrombin III were normal too. With the diagnosis of OHSS in a spontaneous pregnancy, the patient was managed conservatively with bed rest, fluid therapy and Albumin infusion. The patient was discharged after two weeks with the resolution of symptoms.

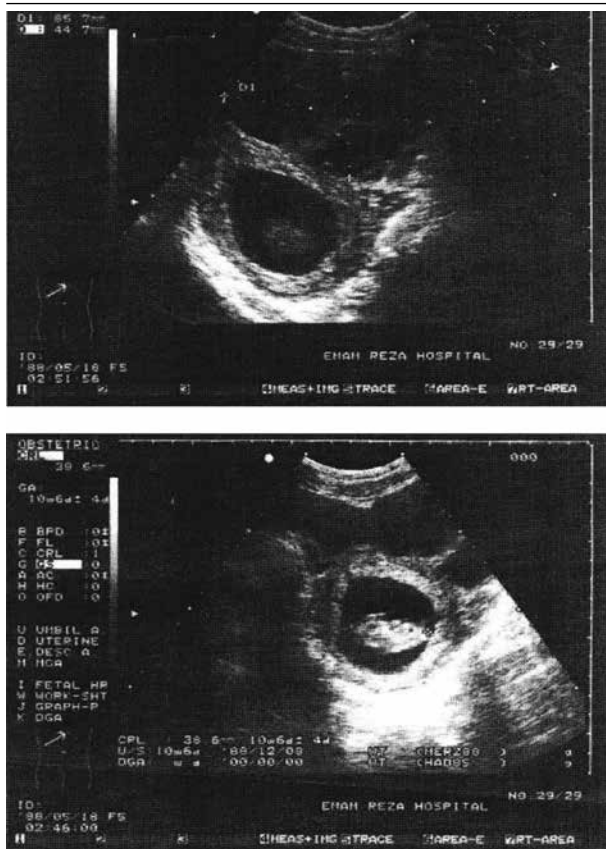


Figure 1. Uterus Ultrasound of the First Case

2.2. The Second Patient

A 26-year-old woman, gravida 2, parity 1, at 11-12 weeks of gestation presented with distention and abdominal tenderness with nausea and vomiting from the beginning of her pregnancy was admitted in the Obstetrics and Gynecology Department of Imam Reza Hospital. Her previous vaginal delivery that was a complete normal pregnancy was 7 years ago. Her menses were regular without any history of hirsutism or other androgenic symptoms, so she did not have PCOS symptoms. She had contraception with IUD and OCP up to 3 months before her pregnancy. This conception had occurred spontaneously. She denied receiving any herbal medication during her present pregnancy. But due to the psychological problems, she has been receiving Doxepin, Citalopram, Cimetidine and Metoclopramide. Her past medical history was normal, only depression and GI problems were seen. Her family history was also normal.

Severe abdominal distention and tenderness was noted in the physical examination. Ultrasonographic findings revealed a pregnancy at 11 ± 1 week with enlarged ovaries, multiloculated cystic ovaries, the biggest of which was reported as 66 mm (Figures 2 and 3). Significant ascites formation has been reported in the pelvic in the abdominal cavity.

Laboratory findings were as follows: hemoglobin 14.1 mg/dL, serum albumin 3.5 gr/dL, liver and kidney function tests were normal. The thyroid function test, Anti cardiolipin antibody (IgG, IgM), Lupus anticoagulant, ANA and CA125 values were normal. Aldosterone and plasma rennin activity values were reported normal. Thrombophilia workup including factor V Leiden, pro C and S activity, homocystein and antithrombin III were normal. The patient was diagnosed with OHSS in a spontaneous pregnancy and she was discharged in a good condition after one week.

3. Discussion

OHSS has been extensively documented in the literature as a complication of treatment with ovulation-inducing agents. Although the etiology still seems to be unclear, human chorionic gonadotropin (HCG) administration is believed to be responsible for events causing increased capillary permeability on the peritoneal and pleural surfaces (14). Spontaneous OHSS without ovarian hyperstimulation is a rare event. However cases of spontaneous OHSS show that endogenous factors may also cause these chains of events. Diagnosis of these factors would help to distinguish other etiologies of OHSS, not only in spontaneous cases, but in infertile ones who are treated with ovulation induction (14).

The first case of spontaneous OHSS was described by Rothmensch in 1989. He described hypothyroidism as a predisposing factor (15). The second one was reported by Zalel in 1992 (16). Other similar cases also described PCOS as only predisposing factor (17). Another case of spontaneous OHSS was reported by Ayhan in 1996. He did not report any evidence of thyroid or PCOS factors (14). No other factors evaluated by Ayhan. Other limited cases

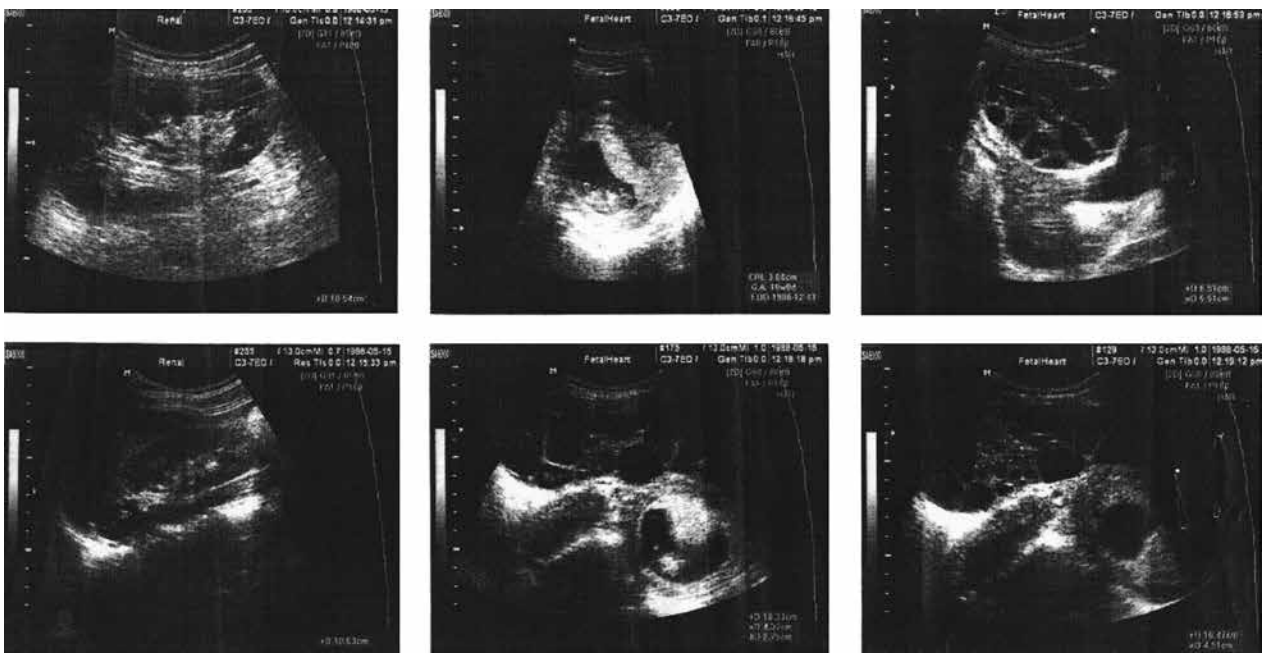


Figure 2. Ultrasound of the Uterus and Ovaries in the Second Case

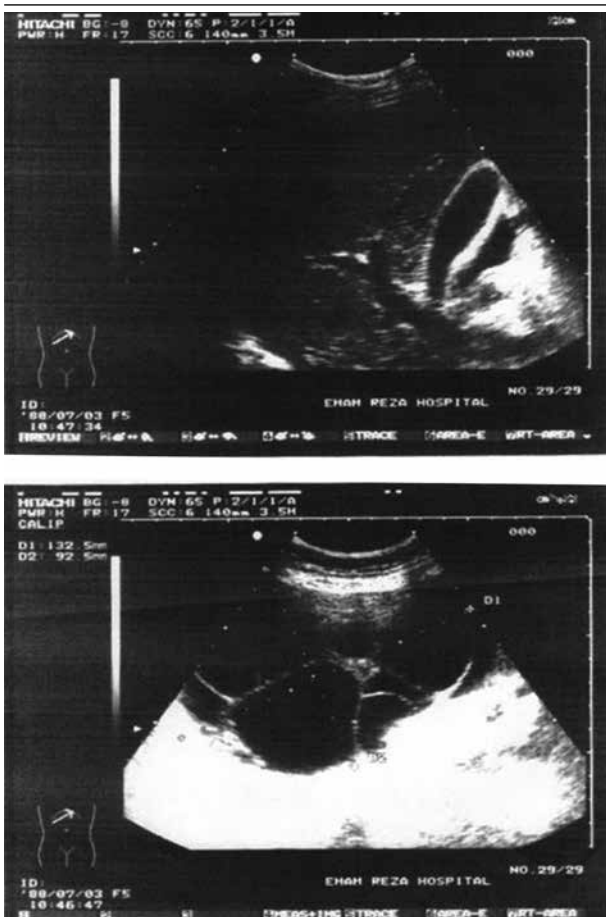


Figure 3. Hyper Stimulated Ovary in the Second Case

of spontaneous OHSS have been reported in literature. Some cases suggest some predisposing factors and some others suggest polycystic ovarian syndrome (PCOS) as an underlying factor (14, 17, 18).

Strafford in 2009 reported a case with complete evacuation of a spontaneously conceived hydatidiform molar pregnancy. He mentioned elevated E2 level without increased VEGF in that case (19). Serum VEGF levels correlated with the clinical severity of OHSS. In the case report by Ludwig et al. OHSS developed in a patient with a partial molar pregnancy and triploids after evacuation of the pregnancy. In that case, the VEGF was normal when it was measured for the first time. But VEGF was very high when she presented with OHSS (20). It is suggested that Follicle-stimulating hormone receptor gene mutations are responsible for the development of OHSS (9, 10, 21). De Leener et al. found a new FSH receptor mutation in patients in whom spontaneous OHSS developed with normal HCG levels (22). Elevated concentration of total rennin, aldosterone and CA125 are reported in spontaneous OHSS (23, 24). Indeed, increased concentrations of these hormones have been reported in OHSS following the ovulation induction. The severity of OHSS correlates with plasma rennin activity (25, 26).

De Leener et al. (22) proposed that the pathogenesis of OHSS can be subdivided into three types. Type 1 is associated with an FSH receptor mutation. Elevated HCG has cross-reactivity with the mutated FSH receptor to cause OHSS during pregnancy. Types 2 and 3 are associated with high levels of HCG (hydatidiform mole) and TSH (hypothyroidism), respectively. Since the amino acid sequences of the hormone-binding domains of the FSH, LH, and TSH

receptors share about 40% identity, high levels of HCG or TAH are able to stimulate the FSH receptor. The majority of the patients with gonadotropin over expression presents with no endocrinology symptoms, although in a few cases, it is associated with endocrinology symptoms. Continuous secretion of FSH by a pituitary adenoma can cause ovarian enlargement (ovarian hyper stimulation) (27, 28).

However, the elevation in E2 caused by the ovarian hyper stimulation suppresses LH which would in turn cause menstrual irregularity. Consequently, spontaneous pregnancy is quite rare in patients with symptomatic FSH-secreting pituitary adenoma. However, the combination of a pituitary adenoma and spontaneous pregnancy causes spontaneous OHSS complicated by severe ascites (13). From limited cases of spontaneous OHSS which are reported till now, some of them are associated with type 1 (9, 10, 13), some with type 2 (H), and some with type 3 (11, 12). With respect to the above information, the clinical courses of our cases resemble none of the mentioned theories. Although, we confronted limited data in evaluation of FSH receptors but all other theories in pathogenesis of spontaneous OHSS were evaluated and all of them were normal. So these cases may suggest other etiological conditions.

Although OHSS is usually an iatrogenic complication of the ovulation induction, it can also occur spontaneously without any evidence of endocrinological disorders. Describing such cases may reveal new etiological predisposing factors.

Acknowledgements

The authors would like to thank Women Health Research Center, vice Chancellor of research, Mashhad University of Medical Sciences, and all coworkers who participated in data collection and statistical analysis.

Authors' Contribution

Study concept and design: Nezhat Mousavifar, Leili Hafizi and Amirreza Reihani. Interpretation of data: Nezhat Mousavifar and Marzieh Ghasemi. Drafting of the manuscript: Leili Hafizi and Marzieh Ghasemi. Follow up: Leili Hafizi and Marzieh Ghasemi. Critical revision of the manuscript for important intellectual content: Leili Hafizi and Amirreza Reihani.

Financial Disclosure

We had no financial interests related to the material in the manuscript.

Funding Support

This paper was funded by the Research Deputy of Mashhad University of Medical Sciences.

References

1. Elchalal U, Schenker JG. The pathophysiology of ovarian hyperstimulation syndrome—views and ideas. *Hum Reprod.* 1997;**12**(6):1129–37.
2. Schenker JG. Clinical aspects of ovarian hyperstimulation syndrome. *Eur J Obstet Gynecol Reprod Biol.* 1999;**85**(1):13–20.
3. Whelan J3, Vlahos NF. The ovarian hyperstimulation syndrome. *Fertil Steril.* 2000;**73**(5):883–96.
4. Goldsman MP, Pedram A, Dominguez CE, Ciuffardi I, Levin E, Asch RH. Increased capillary permeability induced by human follicular fluid: a hypothesis for an ovarian origin of the hyperstimulation syndrome. *Fertil Steril.* 1995;**63**(2):268–72.
5. Levin ER, Rosen GF, Cassidenti DL, Yee B, Meldrum D, Wisot A, et al. Role of vascular endothelial cell growth factor in Ovarian Hyperstimulation Syndrome. *J Clin Invest.* 1998;**102**(11):1978–85.
6. Delbaere A, Bergmann PJ, Gervy-Decoster C, Deschodt-Lanckman M, de Maertelaer V, Staroukine M, et al. Increased angiotensin II in ascites during severe ovarian hyperstimulation syndrome: role of early pregnancy and ovarian gonadotropin stimulation. *Fertil Steril.* 1997;**67**(6):1038–45.
7. Delvigne A, Rozenberg S. Epidemiology and prevention of ovarian hyperstimulation syndrome (OHSS): a review. *Hum Reprod Update.* 2002;**8**(6):559–77.
8. Vasseur C, Rodien P, Beau I, Desroches A, Gerard C, de Poncheville L, et al. A chorionic gonadotropin-sensitive mutation in the follicle-stimulating hormone receptor as a cause of familial gestational spontaneous ovarian hyperstimulation syndrome. *N Engl J Med.* 2003;**349**(8):753–9.
9. Smits G, Olatunbosun O, Delbaere A, Pierson R, Vassart G, Costagliola S. Ovarian hyperstimulation syndrome due to a mutation in the follicle-stimulating hormone receptor. *N Engl J Med.* 2003;**349**(8):760–6.
10. Montanelli L, Delbaere A, Di Carlo C, Nappi C, Smits G, Vassart G, et al. A mutation in the follicle-stimulating hormone receptor as a cause of familial spontaneous ovarian hyperstimulation syndrome. *J Clin Endocrinol Metab.* 2004;**89**(4):1255–8.
11. Cardoso CG, Graca LM, Dias T, Clode N, Soares L. Spontaneous ovarian hyperstimulation and primary hypothyroidism with a naturally conceived pregnancy. *Obstet Gynecol.* 1999;**93**(5 Pt 2):809–11.
12. Edwards-Silva RN, Han CS, Hoang Y, Kao LC. Spontaneous ovarian hyperstimulation in a naturally conceived pregnancy with uncontrolled hypothyroidism. *Obstet Gynecol.* 2008;**111**(2 Pt 2):498–501.
13. Baba T, Endo T, Kitajima Y, Kamiya H, Moriwaka O, Saito T. Spontaneous ovarian hyperstimulation syndrome and pituitary adenoma: incidental pregnancy triggers a catastrophic event. *Fertil Steril.* 2009;**92**(1):390 e1–3.
14. Ayhan A, Tuncer ZS, Aksu AT. Ovarian hyperstimulation syndrome associated with spontaneous pregnancy. *Hum Reprod.* 1996;**11**(8):1600–1.
15. Rotmensch S, Scommegna A. Spontaneous ovarian hyperstimulation syndrome associated with hypothyroidism. *Am J Obstet Gynecol.* 1989;**160**(5 Pt 1):1220–2.
16. Zalel Y, Katz Z, Caspi B, Ben-Hur H, Dgani R, Insler V. Spontaneous ovarian hyperstimulation syndrome concomitant with spontaneous pregnancy in a woman with polycystic ovary disease. *Am J Obstet Gynecol.* 1992;**167**(1):122–4.
17. Zalel Y, Orvieto R, Ben-Rafael Z, Homburg R, Fisher O, Insler V. Recurrent spontaneous ovarian hyperstimulation syndrome associated with polycystic ovary syndrome. *Gynecol Endocrinol.* 1995;**9**(4):313–5.
18. Di Carlo C, Bruno P, Cirillo D, Morgera R, Pellicano M, Nappi C. Increased concentrations of renin, aldosterone and Ca125 in a case of spontaneous, recurrent, familial, severe ovarian hyperstimulation syndrome. *Hum Reprod.* 1997;**12**(10):2115–7.
19. Strafford M, Moreno-Ruiz N, Stubblefield P. Ovarian hyperstimulation syndrome in a spontaneous pregnancy with a complete hydatidiform mole. *Fertil Steril.* 2009;**92**(1):395 e1–3.
20. Ludwig M, Gembruch U, Bauer O, Diedrich K. Ovarian hyperstim-

- ulation syndrome (OHSS) in a spontaneous pregnancy with fetal and placental triploidy: information about the general pathophysiology of OHSS. *Hum Reprod.* 1998;**13**(8):2082-7.
21. Delbaere A, Smits G, Olatunbosun O, Pierson R, Vassart G, Costagliola S. New insights into the pathophysiology of ovarian hyperstimulation syndrome. What makes the difference between spontaneous and iatrogenic syndrome? *Hum Reprod.* 2004;**19**(3):486-9.
 22. De Leener A, Montanelli L, Van Durme J, Chae H, Smits G, Vassart G, et al. Presence and absence of follicle-stimulating hormone receptor mutations provide some insights into spontaneous ovarian hyperstimulation syndrome physiopathology. *J Clin Endocrinol Metab.* 2006;**91**(2):555-62.
 23. Lipitz S, Grisar D, Achiron R, Ben-Baruch G, Schiff E, Mashiach S. Spontaneous ovarian hyperstimulation mimicking an ovarian tumour. *Hum Reprod.* 1996;**11**(4):720-1.
 24. Rosen GF, Lew MW. Severe ovarian hyperstimulation in a spontaneous singleton pregnancy. *Am J Obstet Gynecol.* 1991;**165**(5 Pt 1):1312-3.
 25. Navot D, Margalioth EJ, Laufer N, Birkenfeld A, Relou A, Rosler A, et al. Direct correlation between plasma renin activity and severity of the ovarian hyperstimulation syndrome. *Fertil Steril.* 1987;**48**(1):57-61.
 26. Jager W, Diedrich K, Wildt L. Elevated levels of CA-125 in serum of patients suffering from ovarian hyperstimulation syndrome. *Fertil Steril.* 1987;**48**(4):675-8.
 27. Murakami T, Higashitsuji H, Yoshinaga K, Terada Y, Ito K, Ikeda H. Management of ovarian hyperstimulation due to follicle-stimulating hormone-secreting gonadotroph adenoma. *BJOG.* 2004;**111**(11):1297-300.
 28. Roberts JE, Spandorfer S, Fasouliotis SJ, Lin K, Rosenwaks Z. Spontaneous ovarian hyperstimulation caused by a follicle-stimulating hormone-secreting pituitary adenoma. *Fertil Steril.* 2005;**83**(1):208-10.