

Sub Cortical Osteoid Osteoma of the Capitulum: A Case Report

Karim Pisoudeh,¹ Masoud Mirkazemi,¹ Noushin Aghavali,^{2,*} and Azra IZanloo³

¹Bone and Joint Reconstruction Research Center, Shafa Orthopedic Hospital, Iran University of Medical Sciences, Tehran, IR Iran

²Firoozgar Hospital, Iran University of Medical Sciences, Tehran, IR Iran

³Razavi Cancer Research Center, Razavi Hospital, Imam Reza International University, Mashhad, Iran

*Corresponding author: Noushin Aghavali, Firoozgar Hospital, Iran University of Medical Sciences, Tehran, IR Iran. E-mail: 5132hero@gmail.com

Received 2016 March 27; Accepted 2016 December 04.

Abstract

Osteoid osteoma near the joints is a rare case which is difficult to diagnose. Osteoid osteomas refer to solitary, benign, agonizing lesions of the bone with a nidus of 1.5 to 2 cm, which consists of osteoid, osteoblasts, and varying quantity of fibrovascular stroma. This study reports the case of 37-year-old man with a painful flexion contracture of left elbow for 18 months, then was diagnosed a peri-articular osteoid osteoma. Any attempt for movement, whether passive or active, exacerbated the pain. His conditions was treated as tennis elbow and treated for several months, but his pain persisted continuously. A subcortical osteoid osteoma was observed in fine-cut CT scan within the posterior cortex of the capitulum. Thus, a wide en bloc surgical excision of the nidus was implemented, with total mitigation of pain and quick return to daily activities. It is stressed that history of disease and detailed physical examination can help diagnosis.

Keywords: Osteoid Osteoma, Case Report, Elbow

1. Introduction

In 1935, Jaffe described osteoid osteomas as a distinct entity (1). Osteoid osteomas are solitary, benign, painful lesions of the bone with a nidus of 1.5 to 2 cm that comprises of osteoid, osteoblasts, and varying amounts of fibrovascular stroma (2). The nidus is encircled by area mass of dense and reactive bone. Osteoid osteomas are relatively prevalent benign bone lesions the occurrence of which is intensified only by osteochondromas and nonossifying fibromas.

Osteoid osteomas is estimated to account for approximately 10% - 11% of benign bone tumors and 2% - 3% of all primary bone neoplasms sampled for biopsy (2).

This study reports the case of a 37-year-old man with an 18-month history of severe elbow pain attributed to a subcortical osteoid osteoma in the posterolateral section of his left elbow.

2. Case Presentation

The case was a 37-year-old healthy male worker with an 18-month history of, persistent and severe pain in his left elbow that grew in intensity over time. The patient, had no history of throwing sports, had left work months earlier due to severe pain and disability. The pain deteriorated at night and interrupted his sleep, though it could be partially mitigated by NSAID.

The patient was referred to our clinic and multiple diagnostic tests such as plain radiography, CT scan, MRI and

bone scan were conducted (Figure 1). Whole body bone scan demonstrated higher uptake in left elbow but other tests were normal (Figure 2). The patient had been diagnosed with tennis elbow and treated for 6 months with elbow strap. He also had elbow injection 3 times, but his pain persisted. The results of rheumatologic laboratory were normal.

In early evaluation, the patient did not report any recent mechanical symptoms or instability. The upper extremity of the patient was diffusely atrophic compared to its opposite side, but no signs of skin or temperature abnormality were observed (Figure 3). He displayed severe local tenderness on posterolateral aspect of left elbow. The patient's elbow was flexed at 45°. He was capable of full flexion, pronation, and supination without pain or crepitus. The results of neurovascular examination were normal.

The plain radiography and CT scan were repeated with thin cuts (2 mm) for possible signs of osteoid osteoma and the nidus appeared on radiography and CT slices (Figure 4).

Accordingly, an open en bloc wide-excision biopsy of the nidus with a small rim of normal cortical bone was conducted (Figure 5). For patient suitable orthopedic surgery was done.

The CT scan was performed postoperatively to document nidus excision. The diagnosis was confirmed by histologic report (Figure 6). The patient acquired immediate active range of motion. The pain was completely relieved

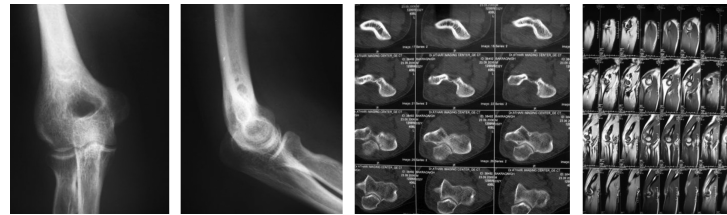


Figure 1. The Results of Imaging Studies at the First Institution, Which Were All Normal

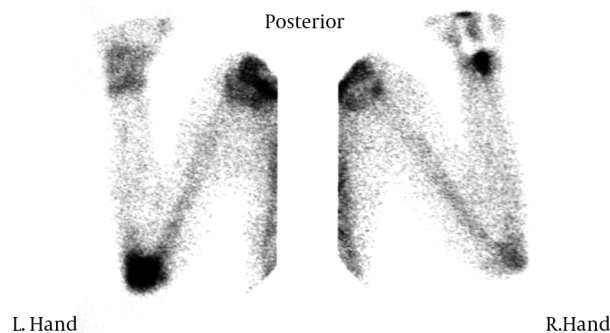


Figure 2. Higher Uptake of Isotope Bone Scanning (In the First Institution)

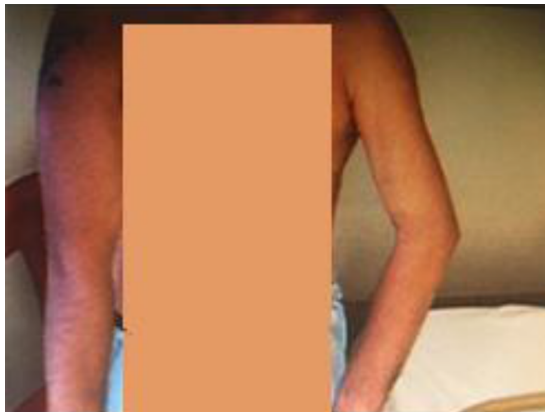

Figure 3. Left Arm and Forearm Muscles Atrophy and Elbow Flexion Contracture

and the patient retained full range of motion with the ability to return to normal (unrestricted) activities 3 weeks after the operation.

The patient signed consent form for presenting of his data.

3. Discussion

Bone pain is the key clinical symptom of osteoid osteoma, which is often augmented by activity and worsened

at night. A careful analysis of disease history and physical examination is required to include osteoid osteoma in the diagnosis of persistent tennis elbow (3). In this case, wide excision or CT-guided radiofrequency ablation can result in predictable and rapid pain relief.

Considering that elbow is not a typical locus of osteoid osteoma, this prolongs to delay the diagnosis of this disease.

If the pain is periarticular, clinical and radiologic manifestations may resemble the inflammatory arthritis or osteomyelitis. The radiologic images often represent them as lack of sclerosis and periosteal reaction (4).

The computed tomography appears to be the best method of diagnosis. The results of magnetic resonance imaging (MRI) should not be interpreted irrespective of plain radiographs and CT scans so as to avoid misdiagnoses (5).

In clinical cases with high suspicion, the imaging studies should be repeated, especially with high-resolution computed tomography with 2 mm cuts.

3.1. Conclusion

Osteoid osteoma should be considered in patients with severe bone pain who lack any obvious clinical diagnosis or radiologic symptoms. The diagnosis could be difficult when the lesion is intracapsular or in rare locations such as elbow. An analysis of disease history and detailed physical examination can help the diagnosis.

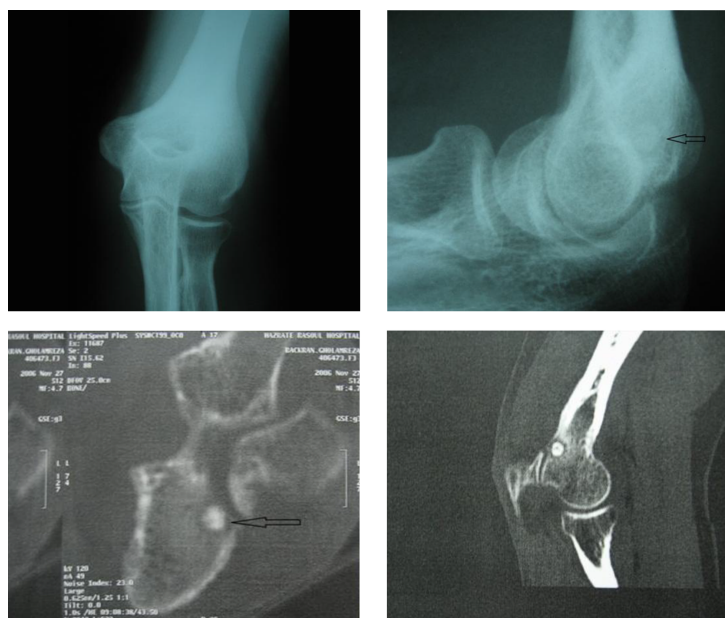


Figure 4. Nidus Was Spotted at Lateral Radiography and CT Scan

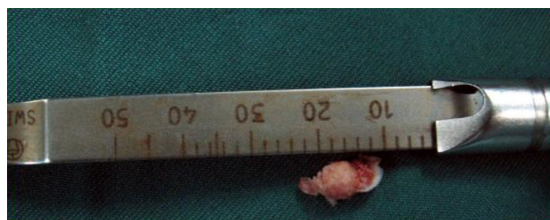

Figure 5. Intraoperative Photograph of the Excised Nidus

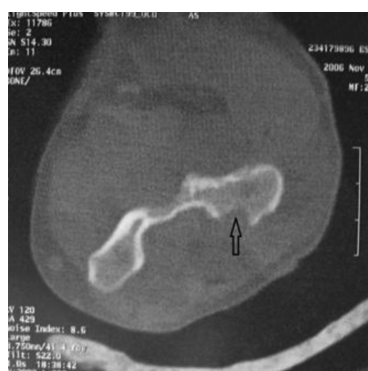

Figure 6. Post Operation CT Scan of the Left Elbow

References

1. Kransdorf MJ, Stull MA, Gilkey FW, Moser RJ. Osteoid osteoma. *Radiographics*. 1991;**11**(4):671-96. doi: [10.1148/radiographics.11.4.1887121](https://doi.org/10.1148/radiographics.11.4.1887121). [PubMed: 1887121].
2. Herring A. Tachojian's pediatric orthopaedics. 4th ed. ; 2008. p. 2221.
3. Albinini U, Bazzocchi A, Bettelli G, Facchini G, Castiello E, Cavaciocchi M, et al. Treatment of osteoid osteoma of the elbow by radiofrequency thermal ablation. *J Shoulder Elbow Surg*. 2014;**23**(1):e1-7. doi: [10.1016/j.jse.2013.08.011](https://doi.org/10.1016/j.jse.2013.08.011). [PubMed: 24331126].
4. Glanzmann MC, Imhoff AB, Schwyzer HK. Osteoid osteoma of the shoulder and elbow: from diagnosis to minimally invasive removal. *Int Orthop*. 2013;**37**(12):2403-8. doi: [10.1007/s00264-013-2060-9](https://doi.org/10.1007/s00264-013-2060-9). [PubMed: 23948984].
5. Ebrahimzadeh MH, Choghadeh MF, Moradi A, Kalati HH, Jafarian AH. Elbow Stiffness Secondary to Elbow Joint Osteoid Osteoma, a Diagnostic Dilemma. *Arch Bone Jt Surg*. 2015;**3**(2):144-7. [PubMed: 2610185].