

Late Spontaneous Dislocation of a Posterior Chamber Intraocular Lens into Anterior Chamber: A Case Report

Khosrow Jadidi,^{1,2,*} and Seyed Aliasghar Mosavi²

¹Department of Ophthalmology, Baqiyatallah University of Medical Sciences, Tehran, Iran

²Department of Ophthalmology, Bina Eye Hospital Research Center, Tehran, Iran

*Corresponding author: Khosrow Jadidi, MD, Associate Professor of Ophthalmology, Department of Ophthalmology, Baqiyatallah University of Medical Sciences, Tehran, Iran. Tel: +98-2188196871, Fax: +98-2188196862, E-mail: kh.jadidi@yahoo.com

Received 2016 January 05; Accepted 2016 October 24.

Abstract

Introduction: Lens luxation generally happens secondary to trauma and hereditary disorders into the vitreous body. However, spontaneous dislocation especially into the anterior chamber occurs rarely. We report an unusual case with spontaneous anterior dislocation of a posterior chamber intraocular lens (IOL) 4 years after cataract surgery.

Case Presentation: A 42-year-old woman was referred to ophthalmology department with complaint of sudden onset blurring of vision in the left eye 4 years after cataract surgery. No history of trauma and systemic disorder was reported and no capsular fibrosis was found during eye examination. The patient underwent corneoscleral incision under general anesthesia and the IOL was extracted using a viscoelastic material.

Conclusions: To our knowledge, this is the first reported case in the literature. This report may imply that IOL related factors could be considered for spontaneous dislocation of intraocular lenses.

Keywords: Intraocular Lens, Cataract Extraction, Lens Subluxation

1. Introduction

Lens luxation generally happens secondary to trauma and hereditary disorders into the vitreous body. However, spontaneous dislocation especially into the anterior chamber occurs rarely (1-5). We report a case of spontaneous luxation of a clear lens to the anterior chamber along with the technique of its surgical removal.

2. Case Presentation

A 42-year-old Iranian woman was referred to the department of ophthalmology, Bina Eye hospital in June 2014 with complaint of sudden deterioration of vision in his left eye one day prior to admission but without any pain. No other abnormalities was detected on general physical examination. Furthermore, past medical history and familial history of the patient were unremarkable with no other history of trauma in the left eye. Ophthalmic examination using slit lamp biomicroscopy revealed IOL dislocation into the anterior chamber (Figure 1). Intraocular pressure (IOP) was 15 mmHg in left eye and 14 mmHg in right eye. No capsular fibrosis was detected in both eyes and no zonules were seen around the dislocated lens. Also, no pseudo exfoliation of the lens capsule was identified in either eye.

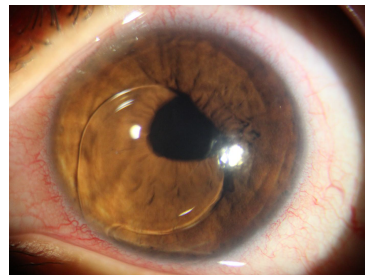

Figure 1. Photograph of a 42-Year-Old Iranian Woman with Lens Dislocation Into the Anterior Chamber

A-scan ultrasonography of both eyeballs demonstrated normal axial length. Manifest refraction was +0.75 - 0.5 × 50 in the right eye and +0.75 - 3.5.00 × 165 in the left eye. The patient underwent corneoscleral incision under general anaesthesia to remove the luxated lens surgically. After making appropriate corneoscleral incision, viscoelastic material (Healon®, AMO Inc,) was injected into the anterior chamber at 11 o'clock between the cornea and the IOL to protect endothelial cells. Subsequently, the whole lens was extracted without difficulty and repositioned with new IOL into the bag. The removed lens was a clear single piece foldable hydrophilic IOL with thin lens design. Postoperatively IOP was 12 mmHg in the left eye

.Cornea was clear without any stromal edema (Figure 2). The patient's condition has remained stable with steady IOP four months after surgery. The corrected visual acuity was 10/10 in both eyes.

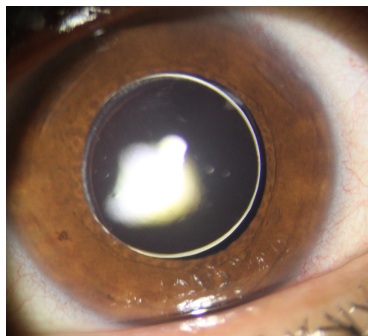


Figure 2. Slit Lamp Photography of the Patient's Left Eye Was Taken Soon After New IOL Replacement. The Visual Acuity Was 9/10, the Cornea Was Clear, and IOP was 13 mmHg

3. Discussion

Etiologically, various risk factors play a role for lens luxation including trauma, heredity, and spontaneous occurrence (1). Trauma is the most common cause in a quantity of 50% of all cases (2-4). Hereditary forms are associated with connective tissue disorders such as Marfan's syndrome, Homocystinuria, Weill-Marchesani syndrome, Ehler-Danlos, and Scleroderma and some cases of spontaneous luxation (5).

Our case was one of the most unusual and rare form of spontaneous dislocation of the intraocular lens into the anterior chamber. The cause of spontaneous lens luxation in our patient is unknown.

In one hand, all of the work-ups were negative for known risk factors in this patient including Vascular diseases, Diabetes mellitus, Chronic venous insufficiency, Zonular weakness, Chronic intraocular inflammation, Aging, Sickle cell disease, Cancer therapy, Retinitis pigmentosa, Malnutrition, Coagulation disorders, smoking and high myopia (1-6).

On the other hand, no capsular fibrosis was detected in our case. Capsule fibrosis is a risk factor causing IOL dislocation or decentration that can occur after phacoemulsification from 2 weeks to more than 3 months that yields mesenchymal transition and differentiation to fiber-like cells (7, 8). Metaplasia and fibrosis of these cells may be exaggerated when there is an imbalance between centrifugal and centripetal forces that act on the zonules and the capsulorhexis perimeter (9). Therefore, other factors may play a role for lens luxation in our case.

Study of Joo et al. (1995) found that the type of IOL plays an important role in the development and severity of capsular fibrosis. Silicone, acrylic, plate haptic, and poly HEMA IOLs have been associated with higher rates and more pronounced phimosis when compared to PMMA IOLs (10).

In our case, we used a single piece foldable hydrophilic IOL. Since the lens design was thin and the haptic was not tightly placed inside the bag, the chance of the IOL instability rises that may explain our finding. However, the role of other systemic factors cannot be overlooked.

Several studies recommended immediate removal of a lens to prevent severe complications during lens dislocation into the anterior chamber (2, 11). In our case, we did lens extraction through a corneoscleral incision without vitrectomy because there was no vitreous in the anterior chamber. In order to protect endothelial cells during surgical invasion and maintenance of corneal clarity, we used viscoelastic material. Using this technique allowed minimum surgical invasion and uneventful, fast and successful postoperative recovery.

In conclusion, we report a successful case of lens extraction in a patient with a foldable hydrophilic IOL that spontaneously dislocated into the anterior chamber. Careful selection of suitable lens design and material is necessary; hydrophilic lens material and a thin lens design may result in early spontaneous dislocation of IOL.

Footnotes

Financial Support: No financial support was received for this submission.

Conflict of Interest Statement: None of the authors has a conflict of interest with this submission.

References

1. Kawashima M, Kawakita T, Shimazaki J. Complete spontaneous crystalline lens dislocation into the anterior chamber with severe corneal endothelial cell loss. *Cornea*. 2007;**26**(4):487-9. doi: [10.1097/ICO.0b013e3180303ae7](https://doi.org/10.1097/ICO.0b013e3180303ae7). [PubMed: [17457202](https://pubmed.ncbi.nlm.nih.gov/17457202/)].
2. Choi DY, Kim JG, Song BJ. Surgical management of crystalline lens dislocation into the anterior chamber with corneal touch and secondary glaucoma. *J Cataract Refract Surg*. 2004;**30**(3):718-21. doi: [10.1016/j.jcrs.2003.07.012](https://doi.org/10.1016/j.jcrs.2003.07.012). [PubMed: [15050275](https://pubmed.ncbi.nlm.nih.gov/15050275/)].
3. Netland KE, Martinez J, LaCour O3, Netland PA. Traumatic anterior lens dislocation: a case report. *J Emerg Med*. 1999;**17**(4):637-9. [PubMed: [10431953](https://pubmed.ncbi.nlm.nih.gov/10431953/)].
4. Jaffe NS, Jaffe MS, Jaffe GF. *Cataract surgery and its complications*. 6th ed. Mosby St. Louis; 1997.
5. Cionni RJ. *Cataract Surgery: Technique, Complications, and Management*. Philadelphia: Saunders; 2004. pp. 305-13. Surgical management of the congenitally subluxated crystalline lens using the modified capsular tension ring.
6. Pop R. [Spontaneous luxation of the crystalline lens into the anterior chamber (a clinical case report)]. *Oftalmologia*. 1992;**36**(1):61-3. [PubMed: [1520672](https://pubmed.ncbi.nlm.nih.gov/1520672/)].

7. Marcantonio JM, Rakic JM, Vrensen GF, Duncan G. Lens cell populations studied in human donor capsular bags with implanted intraocular lenses. *Invest Ophthalmol Vis Sci.* 2000;**41**(5):1130-41. [PubMed: [10752951](#)].
8. Davison JA. Capsule contraction syndrome. *J Cataract Refract Surg.* 1993;**19**(5):582-9. doi: [10.1016/S0886-3350\(13\)80004-1](#). [PubMed: [8229711](#)].
9. Jin-Poi T, Shatriah I, Khairy-Shamel ST, Zunaina E. Rapid anterior capsular contraction after phacoemulsification surgery in a patient with retinitis pigmentosa. *Clin Ophthalmol.* 2013;**7**:839-42. doi: [10.2147/OPHT.S42122](#). [PubMed: [23674886](#)].
10. Joo CK, Shin JA, Kim JH. Capsular opening contraction after continuous curvilinear capsulorhexis and intraocular lens implantation. *J Cataract Refract Surg.* 1996;**22**(5):585-90. doi: [10.1016/S0886-3350\(96\)80014-9](#). [PubMed: [8784631](#)].
11. Peyman GA, Raichand M, Goldberg MF, Ritacca D. Management of subluxated and dislocated lenses with the vitrophage. *Br J Ophthalmol.* 1979;**63**(11):771-8. doi: [10.1136/bjo.63.11.771](#). [PubMed: [315794](#)].